

# Brief Communication: Applying Metal Clips at the Tip of Gastrojejunostomy Stapling Site to Reduce Intraluminal Early Postoperative Bleeding



Barmak Gholizadeh<sup>1,2</sup> , Behnam Reza Makhsosi<sup>3</sup> , Abdolreza Pazouki<sup>1,4\*</sup> 

1. Minimally Invasive Surgery Research Center, Iran University of Medical Sciences, Tehran, Iran.

2. Department of General Surgery, Shahid Modarres Hospital, Shahid Beheshti University of Medical Sciences, Tehran, Iran.

3. Department of General Surgery, Kermanshah University of Medical Sciences, Kermanshah, Iran.

4. Center of Excellence of International Federation for Surgery of Obesity and Metabolic Disorders, Tehran, Iran.



**Please cite this article as** Gholizadeh B, Makhsosi BR, Pazouki A. Applying Metal Clips at the Tip of Gastrojejunostomy Stapling Site to Reduce Intraluminal Early Postoperative Bleeding. *Annals of Bariatric Surgery*. 2021; 10(1):53-56. <http://dx.doi.org/10.32598/ABS.10.1.8>

 <http://dx.doi.org/10.32598/ABS.10.1.8>



## Article info:

Received: 12 Jun 2021

Accepted: 22 Jun 2021

Publish: 30 Jun 2021

## Keywords:

Gastric bypass, Bariatric surgery, Postoperative hemorrhage

## ABSTRACT

Nowadays, the surgical option is the most potent and durable treatment modality for morbidly obese patients worldwide. Early and late postoperative gastrointestinal bleeding is one complication encountered after bariatric surgery. One of the probable locations of gastrointestinal bleeding after gastric bypass is the gastrojejunostomy anastomosis site. The use of metal clips in the tip of the inner aspect of gastrojejunostomy anastomosis may reduce intraluminal bleeding in the early postoperative period.

## 1. Introduction

Obesity is one of the significant challenges all over the world for the health system [1]. Nowadays, death rates related to obesity and overweight are higher than starvation [1]. Control of morbid obesity is essential for health systems to improve obesity-related comorbidities and reduce its mortality [2, 3]. In morbidly

obese patients, non-operative treatment modalities have failed to show good outcomes. Nowadays, the surgical option is the most potent and durable treatment modality for morbidly obese patients in the world [4]. Because of the higher frequency of performing bariatric surgery globally, bariatric surgeons should be aware of its even rare complications and ways to prevent them. Early and late postoperative Gastrointestinal Bleeding (GIB) is one of these complications [5]. One of the probable locations

### \* Corresponding Author:

Abdolreza Pazouki, MD, MIS Fellowship

Address: Minimally Invasive Surgery Research Center, Iran University of Medical Sciences, Tehran, Iran.

E-mail: apazouki@yahoo.com

of GIB after gastric bypass is the gastrojejunostomy anastomosis site [5].

There are some anastomotic techniques of gastrojejunostomy, such as circular stapling and linear stapling [6]. Linear stapling technique for gastrojejunostomy causes a lower incidence of GIB than circular stapling [7]. In our research, the overall risk of GIB from gastrojejunostomy sites was about 2%, which is high in these types of elective procedures [6]. We present a new innovative technique that could lower GIB from gastrojejunostomy anastomosis.

### Surgical technique

After creating the gastric pouch, the anastomotic site was defatted, and an orifice for a linear stapler was created using an electrocautery device. We usually determine the location in the posterior aspect of the pouch about 1 cm from the tip. After determining the appropriate place in the intestine based on the procedure type, the enterotomy is performed in the antimesenteric site of the small intestine. Then, the inferior jaw of the stapler is inserted in the intestine, and the stapler and intestine are placed near the pouch; finally, another jaw of the stapler is inserted in the pouch, and the stapler firing is performed.

After firing the linear stapler, the inner stapler line is visualized with the help of a single-action instrument on the right side and suction irrigation device on the left side of the orifice. Pulsatile suctioning in the lumen helps good visualization of the inner stapler line. After the exposure of the inner staple line, a metal clip is applied to the tip of the gastrojejunostomy site to reduce the intraluminal bleeding (Figure 1). The later stages of operation are performed in the usual manner. This technique is very helpful in decreasing early postoperative intraluminal bleeding.

## 2. Discussion

Early upper GIB in postoperative bariatric patients may occur from gastrojejunostomy site after gastric bypass operations such as One Anastomosis Gastric Bypass (OAGB) and Roux-en-Y Gastric Bypass (RYGB) [5]. Its incidence ranges between 1.9% and 4.4% in literature [5].

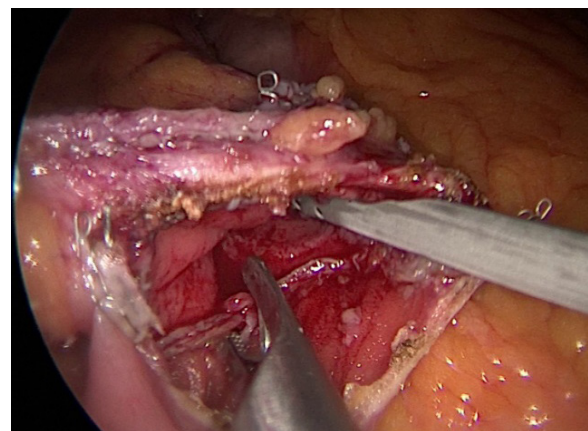
Between different gastrojejunostomy techniques, the Linear Stapling (LS) technique is mainly known for its lower bleeding incidence than the Circular Stapling (CS) technique (2% and 3.5%) [6]. These results maybe because of the number of stapler rows in LS and CS. LS has 3 rows of staplers, whereas CS has 2 rows [8]. Despite using linear stapling with appropriate stapler height, the overall early

postoperative bleeding rate is about 2%, which is high for this type of elective operation [6, 9].

We think that using linear stapling cartilages may reduce bleeding occurrence from sides of gastrojejunostomy anastomosis, but these staplers could not prevent bleeding occurrence from the tip of gastrojejunostomy. Because of this hypothesis, we developed a technique to reduce early postoperative intraluminal bleeding in gastric bypass surgeries. In this technique, we use metal clips in the tip of the inner aspect of gastrojejunostomy anastomosis to reduce intraluminal bleeding (Figure 1).

There are some concerns about applying metal clips in the gastrojejunostomy site. First of all, these clips reduce the bleeding, but applying metal clips may cause some complications such as intestinal perforation and play as a foreign body to predispose for marginal ulcer. Our previous experience in gastric bypass patients was about 2% early intraluminal bleeding requiring endoscopic intervention, consistent with the reported incidence in the literature [5-7]. But after applying this technique in about 500 patients, the intraluminal bleeding occurred in only one patient (0.2%), which is a good result.

In our experience in these 500 patients, there were no cases of intestinal perforation related to clips applying, and rates of marginal ulcers were not increased after 6 months follow up. This complication may be because of clips drop and excretion from stool because of rapid regeneration of intestinal mucosa. In this article, we report our experience, which we found very helpful in decreasing early postoperative intraluminal bleeding. A randomized clinical trial with longer follow-up is needed to support our claim.



**Figure 1.** Applying metal clips in the tip of inner aspect of gastrojejunostomy anastomosis

## Ethical Considerations

### Compliance with ethical guidelines

All ethical principles are considered in this article. The participants were informed about the purpose of the research and its implementation stages. They were also assured about the confidentiality of their information. They were free to leave the study whenever they wished, and if desired, the research results would be available to them.

### Funding

This research did not receive any grant from funding agencies in the public, commercial, or non-profit sectors.

### Authors' contributions

All authors equally contributed in preparing this article.

### Conflict of interest

The authors declared no conflict of interest.

Techniki Maloinwazyjne. 2017; 12(2):140-6. [DOI:10.5114/wiitm.2017.66868] [PMID] [PMCID]

- [7] Romeijn MM, van Hoef S, Janssen L, van de Pas KGH, van Dielen FM, Luijten AAPM, et al. Comparison of linear versus circular-stapled gastroenterostomy in roux-en-y gastric bypass: A nationwide population-based cohort study. *Obesity Surgery*. 2021; 31(8):3579-87. [DOI:10.1007/s11695-021-05436-4] [PMID] [PMCID]
- [8] Finks JF, Carlin A, Share D, O'Reilly A, Fan Z, Birkmeyer J, et al. Effect of surgical techniques on clinical outcomes after laparoscopic gastric bypass: Results from the Michigan Bariatric Surgery Collaborative. *Surgery for Obesity and Related Diseases*. 2011; 7(3):284-9. [DOI:10.1016/j.soard.2010.10.004] [PMID]
- [9] Nguyen NT, Dakin G, Needleman B, Pomp A, Mikami D, Provost DA, et al. Effect of staple height on gastrojejunostomy during laparoscopic gastric bypass: A multicenter prospective randomized trial. *Surgery for Obesity and Related Diseases*. 2010; 6(5):477-82. [DOI:10.1016/j.soard.2010.03.294] [PMID]

## References

- [1] WHO (World Health Organization). Obesity and overweight fact sheet. [Internet]. 2016 [Updated 9 June 2021]. Available from: <https://www.who.int/news-room/fact-sheets/detail/obesity-and-overweight>
- [2] Doumouras AG, Hong D, Lee Y, Tarride JE, Paterson JM, Anvari M. Association between bariatric surgery and all-cause mortality: A population-based matched cohort study in a universal health care system. *Annals of Internal Medicine*. 2020; 173(9):694-703. [DOI:10.7326/M19-3925] [PMID]
- [3] Sheng B, Truong K, Spitler H, Zhang L, Tong X, Chen L. The long-term effects of bariatric surgery on type 2 diabetes remission, microvascular and macrovascular complications, and mortality: A systematic review and meta-analysis. *Obesity Surgery*. 2017; 27(10):2724-32. [DOI:10.1007/s11695-017-2866-4] [PMID]
- [4] Arterburn DE, Telem DA, Kushner RF, Courcoulas AP. Benefits and risks of bariatric surgery in adults: A review. *JAMA*. 2020; 324(9):879-87. [DOI:10.1001/jama.2020.12567] [PMID]
- [5] Acquafresca PA, Palermo M, Rogula T, Duza GE, Serra E. Early surgical complications after gastric by-pass: A literature review. *Brazilian Archives of Digestive Surgery*. 2015; 28(1):74-80. [DOI:10.1590/s0102-67202015000100019] [PMID] [PMCID]
- [6] Major P, Janik MR, Wysocki M, Wałędziak M, Pędziwiatr M, Kowalewski PK, et al. Comparison of circular-and linear-stapled gastrojejunostomy in laparoscopic Roux-en-Y gastric bypass: A multicenter study. *Wideochirurgia I Inne*

This Page Intentionally Left Blank