



Five Years' Experience on Hysteroscopy in Abnormal Vaginal Bleeding

Mansoureh Vahdat¹, Elaheh Sariri¹, Maryam Kashanian², Zahra Najmi^{1,*}, Mahjabin Marashi³, Behnaz Mohabbatian³, Sara Asadollah³, Nahid Khorshidi⁴

¹ Department of Obstetrics and Gynecology, Minimally Invasive Surgery Research Center, Rasool-e-Akram Hospital, Tehran University of Medical Sciences, Tehran, IR Iran

² Department of Obstetrics and Gynecology, Shahid Akbarabadi Hospital, Tehran University of Medical Sciences, Tehran, IR Iran

³ Department of Obstetrics and Gynecology, Tehran University of Medical Sciences, Tehran, IR Iran.

⁴ Department of Obstetrics and Gynecology, Shahid Beheshti University of Medical Sciences, Tehran, IR Iran

*Corresponding author: Zahra Najmi, Department of Obstetrics and Gynecology, Minimally Invasive Surgery Research Center, Rasool-e-Akram Hospital, Tehran University of Medical Sciences, Tehran, IR Iran. Tel/Fax: +98-2166517342, E-mail: zahranaaj@student.tums.ac.ir..

ABSTRACT

Background: Hysteroscopy is the gold standard method for diagnosis of intrauterine pathologies. Current study is a review of hysteroscopic findings performed over a period of 5 years in patients with abnormal uterine bleeding (AUB).

Objective: The aim of this study was a review of hysteroscopic findings performed over a period of 5 years in patients with abnormal uterine bleeding (AUB).

Patients and Materials: This descriptive analytic study was conducted prospectively on patients in reproductive, premenopausal or postmenopausal ages referring to our hospital with complaint of AUB. All patients underwent hysteroscopy (either diagnostic or therapeutic) by the same surgeons. Analysis was performed on the base of the hysteroscopic findings.

Results: In our population study (379 patients) major menstrual pattern was menometrorrhagia. The most common diagnoses at operative hysteroscopy were endometrial polyps (17.8%), hyperplastic endometrium (15.2%), and uterine submucosal myoma (9.7%). The most common findings in patients with menometrorrhagia were myoma, and polyp where, the most common finding in patients with menorrhagia, and metrorrhagia was polyp. Our major complications were uterine perforation in 9, thermal injury in 3, and air emboli in one case.

Conclusions: In current study the most common pathology was found to be endometrial polyp. Myoma was the most common finding in patients with menometrorrhagic bleeding. Our major complications were uterine perforation, thermal injury, and air emboli.

Keywords: Uterine Hemorrhage; Endometrial hyperplasia; Hysteroscopy; Myoma

► Article type: Research Article; Received: 22 Nov 2012, Revised: 14 Feb 2013, Accepted: 16 Feb 2013; Epub: 30 June 2013;

► Implication for health policy/practice/research/medical education:

The aim of this study was a review of hysteroscopic findings performed over a period of 5 years in patients with abnormal uterine bleeding (AUB).

► Please cite this paper as:

Vahdat M, Sariri E, Kashanian M, Najmi Z, Marashi M, Mohabbatian B, Asadollah S, Khorshidi N. Five Years' Experience on Hysteroscopy in Abnormal Vaginal Bleeding. J Minim Invasive Surg Sci. 2013; 2(3): 13-7.

► Copyright © 2013, Minimally Invasive Surgery Research Center and Mediterranean and Middle Eastern Endoscopic Surgery Association.

This is an Open Access article distributed under the terms of the Creative Commons Attribution License (<http://creativecommons.org/licenses/by/3.0>), which permits unrestricted use, distribution, and reproduction in any medium, provided the original work is properly cited.

1. Background

Hysteroscopy is one of the new diagnostic methods in gynecology with a relatively recent development (1). This procedure has been found to be a totally reliable method for the study of abnormal uterine bleeding (AUB) compared to histological tests (2). Hysteroscopy has been generally accepted as the gold standard method for evaluation of the uterine cavity (3). The most important benefit of hysteroscopy is its "see and treat" potential, which not only avoids multiple hospital visits, but also provides higher patient satisfaction (4). However to get the maximum benefit from this procedure, it is important to select patients properly, and the investigation should be performed by skilled personnel to obtain optimal results, so that patients are managed adequately and cost effectively (5). With high sensitivity and specificity of this method in diagnosis of uterine lesions, due to its high accuracy, and patient acceptance, and low complication rate (less than 2% of cases), it can be used as an ideal diagnostic tool to assess patients with AUB (6). Here we present a review of hysteroscopic procedures performed over a period of 5 years. The aim of this study was a review of hysteroscopic findings performed in our referral endoscopic surgery center over a period of 5 years in patients with complaint of AUB.

2. Objective

The aim of this study was a review of hysteroscopic findings performed over a period of 5 years in patients with abnormal uterine bleeding (AUB).

3. Patients and Materials

This was a descriptive analytic study conducted prospectively on patients in reproductive, premenopausal or postmenopausal ages referring to Rasoul-E-Akram hospital in Tehran for AUB. 400 patients were enrolled consecutively; the study was began in Sep 2006 and ended in Sep 2010. The inclusion criteria were: patients in reproductive, premenopausal, or postmenopausal ages who either complain from abnormal vaginal bleeding or increased endometrial thickness (ET), with normal findings of Pap smear test, and no hormonal abnormality. Increased ET was defined as ultrasound measured endometrial thickness greater than 12 mm in premenopause, and 5mm in postmenopause women. The excluding criteria were: virgin subjects, patients with contraindications for general anesthesia, pregnant or pregnancy suspected subjects, active gynecologic infections, known cases of endometrial cancer, or malignant cervical lesions. The study and procedures were explained to the patients before entering the study. All of the procedures were performed by same gynecologists using the hysteroscopy set (Olympus, Germany). In the presence of any pathologic lesion, biopsy was taken, and after removing

the hysteroscope, routine dilatation, and curettage were performed, and the reports were recorded. All pathologic studies of the hysteroscopic biopsies and curettage materials were performed by the same pathologist. Data was registered in checklists including demographic characteristics, patient's complaints, hysteroscopy findings, and pathology results. They were coded, and analyzed by SPSS for Windows version 19 (SPSS Inc., Chicago, IL, USA). Numerical variables were reported as mean \pm standard deviation (SD) when normally distributed, otherwise as median and range. P value \leq 0.05 was considered to be statistically significant.

4. Results

Over the 5-year period from Sep 2006 to Sep 2010, 745 hysteroscopic procedures were performed in our referral center, 400 of which were performed for patient with either abnormal vaginal bleeding or increased endometrial thickness (ET) to discover the true nature of uterine pathology. Analysis was performed on the complete data of 379 of patients, and other 21 patients who had incomplete data were not included. The mean age of the patients was 39.31 ± 11.01 years (ranging from 16 to 83). Major menstrual pattern was menometrorrhagia. Patient's baseline characteristics are summarized in (Table 1). The most common indication for diagnostic hysteroscopy was abnormal bleeding in the premenopausal or bleeding in the postmenopausal period. The most common diagnoses at operative hysteroscopy were endometrial polyps (17.8%), hyperplastic endometrium (15.2%), and uterine submucosal myoma (9.7%). In 27.2% of cases, no obvious pathology was detected (Table 2, Figure 1). The most common indications for operative (therapeutic) hysteroscopy were polypectomy (22.3%), and myomectomy (17.3%). The most common finding in patients with menometrorrhagia was myoma, and polyp where, the most common finding in patients with menorrhagia and metrorrhagia was polyp (Table 3). Hysteroscopic findings in postmenopausal group were as follows: endometrial atrophy, endometrial, and cervical polyps, endometrial hyperplasia, and endometrial cancer in 53.1%, 28.1%, 15.6%, and 3.1%, respectively. One patient expired during hysteroscopy due to acute air emboli, who was a known case of liver cirrhosis. Uterine perforation with cold instruments occurred in 9 patients. None of them needed additional surgical intervention, and their early and late postoperative were uneventful. Thermal injuries during myoma resection occurred in 3 patients. They underwent laparotomy for evaluating the extent of injury. Injuries were limited to the uterus in two but in the other one cecum was injured, and needed repair. No case of fluid overload was noted. No complications occurred during dilatation of the cervix. We had no late complications except for pelvic infection in two patients in 7, and 10 postoperative days (Table 4).

Table 1. Base Line Characteristics of the Study Population (n = 379)

Indication of Hysteroscopy, No. (%)	
AUB	252 (66)
Increased ET	22 (5.8)
AUB and Increased ET	108 (28.3)
Age, y, Mean ± SD	39.31 ± 11.01
Gravidity, Mean ± SD	3.26 ± 2.29
Parity, Mean ± SD	2.74 ± 2.11
Nulliparity, No. (%)	42 (11)
AUB duration, month, Mean ± SD	22.61 ± 27.42
Marriage duration, y, Mean ± SD	19.65 ± 11.42
Tubal ligation, No. (%)	84 (22)
Tubal ligation duration, y, Mean ± SD	11.10 ± 5.54
Mensural Pattern, No. (%)	
Regular	22 (5.8)
Menorrhagia	68 (17.8)
Metrorrhagia	33 (8.6)
Menometrorrhagia	199 (52.1)
Olygomenorrhea	24 (6.3)
Amenorrhea	4 (1)
Menopausal	32 (8.4)
Dysmenorrhea, No. (%)	55 (14.4)
Dyspareunia, No. (%)	34 (8.9)
Post coital bleeding, No. (%)	21 (5.5)

Table 2. Hysteroscopic Findings of the Study Population

Normal Cavity, No. (%)	104 (27.2)
Polyps, No. (%)	
Endometrial	68 (17.8)
Cervical	17 (4.5)
Myomas, No. (%)	
Submucosal	37 (9.7)
Intramural	23 (6)
Cervical	6 (1.6)
Hyperplastic endometrium, No. (%)	58 (15.2)
Atrophic endometrium, No. (%)	6 (1.6)
Bicornate uterus, No. (%)	2 (0.5)
Septate uterus, No. (%)	15 (3.9)
Conception, No. (%)	29 (7.6)
Asherman, No. (%)	8 (2.1)
Adenomyosis, No. (%)	9 (2.4)

Table 3. Hysteroscopic Findings in Different Menstrual Patterns

Menometrorrhagia (n = 199)	No. (%)
----------------------------	---------

Myoma	51 (25.62)
Polyp	42 (21.10)
Hyperplasia	33 (16.58)
Atrophy	0
Septum	4 (2.01)
Asherman	4 (2.01)

Menorrhagia (n = 68)

Myoma	11 (16.17)
Polyp	15 (22.05)
Hyperplasia	12 (17.64)
Atrophy	0
Septum	5 (7.35)
Asherman	2 (2.94)

Metrorrhagia (n = 33)

Myoma	3 (9.09)
Polyp	10 (30.30)
Hyperplasia	4 (12.12)
Atrophy	2 (6.06)
Septum	3 (9.09)
Asherman	0

Olygomenorrhea (n = 24)

Myoma	0
Polyp	3 (12.5)
Hyperplasia	4 (16.66)
Atrophy	0
Septum	3 (12.5)
Asherman	1 (4.10)

Amenorrhea (n = 4)

Myoma	0
Polyp	0
Hyperplasia	0
Atrophy	0
Septum	0
Asherman	1 (25)

Table 4. Intraoperative, and Postoperative Complications of the Study Population

Complications	No. (%)
Air Emboli	1 (0.26)
Cold instrument uterine injury	9 (2.37)
Thermal Injury	3 (0.79)
Uterus only	2 (0.52)
Cecum	1 (0.26)
Pelvic infections	2 (0.52)
Fluid overload	0
Complications during dilatation of cervix	0

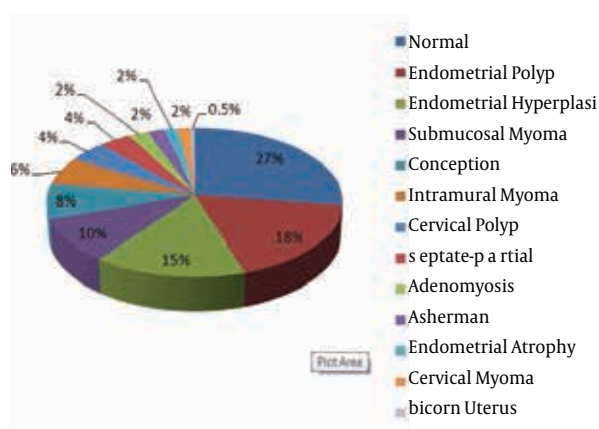


Figure 1. Hysteroscopic Findings of the Study Population

5. Discussion

Hysteroscopy is a minimally invasive procedure, and generally considered to be the golden standard for diagnosis of intrauterine pathologies. In the current study the most common hysteroscopic findings in premenopausal women were endometrial polyps followed by hyperplastic endometrium, and uterine submucosal myoma. The most common indications for operative hysteroscopy were polypectomy, and myomectomy. The most common finding in patients with menometrorrhagia was myoma, and polyp where, the most common finding in patients with menorrhagia and metrorrhagia was polyp. In postmenopausal group the most common diagnosis was endometrial atrophy followed by endometrial and cervical polyps, endometrial hyperplasia, and endometrial cancer. Cancers comprise the etiology of only 3.1% of postmenopausal bleeding. The most prevalent menstrual pattern in our study population was menometrorrhagia, and the most common cause of this pattern was uterine myoma. However, in some studies the most common cause found to be intrauterine polyps (3). Abnormal perimenopausal, and postmenopausal bleeding should always be taken seriously and be properly investigated, no matter how minimal or nonpersistent. Causes may be nongenital, extra uterine, or uterine (7). Possible uterine causes of premenopausal or postmenopausal bleeding include endometrial atrophy, endometrial polyps, estrogen therapy, hyperplasia, and cancer or sarcoma (7). Endometrial atrophy is the most common endometrial finding in women with postmenopausal bleeding, accounts for 60% to 80% of such bleeding (7). Our results showed the prevalence of 53.1% which is comparable. Polyps are often difficult to identify with office endometrial biopsy or curettage. Hysteroscopy may be a useful adjunct in identifying endometrial polyps (8). We found polyps in 28.1% of our procedures. Endometrial hyperplasia occurs in 5% to 10% of patients with postmenopausal uterine bleeding,

but we found 15.6% having hyperplasia. There were some cases over diagnosed by hysteroscopy as endometrial hyperplasia, but no cases of hyperplasia were missed by this procedure. The source of excess estrogen should be considered, including obesity, exogenous estrogen, or an estrogen-secreting ovarian tumor. Only about 10% of patients with postmenopausal bleeding have endometrial cancer (7). Our data showed a lower rate of cancer in postmenopausal bleedings (3.1%). In line with other studies the major complications in our study population were in operative (therapeutic) hysteroscopies (9, 10). The acute complications were found to be uterine perforation by either cold or thermal injuries, which is similar to that reported by other authors (9-11). In one study (12) fluid overload was the most common complication, however, we found no such complications. We had also 2 cases of postoperative pelvic infections. The main limitation of the present trial was its uni-center design which limits its generalizability to other populations. However, correlating our data with that reported in other studies, we find hysteroscopy to be a safe and effective minimally invasive procedure with a low rate of complications. The findings in postmenopausal women correlated well with previous studies, but we found some difference in causes of abnormal bleeding in premenopausal women.

Acknowledgements

None declared

Authors' Contribution

Mansoureh Vahdat, Elaheh Sariri, and Nahid Khorshidi: performing the Hysteroscopic procedures, Maryam Kashanian, and Zahra Najmi: collecting the data and drafting, Mahjabin Marashi, Behnaz Mohabbatian, and Sara Asadollah: collecting the data

Financial Disclosure

We declare that we had no conflicts of interest

Funding Support

We had no funding support

References

1. Caserta D, Toro G, Porretta M, Mancini E, Moscarini M. [Hysteroscopic vs histologic diagnosis. Study of 222 cases of abnormal uterine hemorrhage]. *Minerva Ginecol.*1999;**51**(5):169-72
2. Lalchandani S, Phillips K. Evaluation of endometrial cavity—investigation options. *Rev Gynaecolog Pract.*2003;**3**(3):165-170
3. Koskas M, Mergui JL, Yazbeck C, Uzan S, Nizard J. Office hysteroscopy for infertility: a series of 557 consecutive cases. *Obstet Gynecol Int.*2010;**2010**:168096
4. Guido R,S, Stovall DW. Hysteroscopy. *Official reprint from Up To Date.*;20(1)
5. Lo KW, Yuen PM. The role of outpatient diagnostic hysteroscopy in identifying anatomic pathology and histopathology in the endometrial cavity. *J Am Assoc Gynecol Laparosc.*2000;**7**(3):381-5

6. Mettler L, Wendland EM, Patel P, Caballero R, Schollmeyer T. Hysteroscopy: an analysis of 2-years' experience. *JLS*.2002;**6**(3):195-7
7. Berek JS. *Berek and Novak's Gynecology*.2012.
8. Fatemi HM, Kasius JC, Timmermans A, van Disseldorp J, Fauser BC, Devroey P, et al. Prevalence of unsuspected uterine cavity abnormalities diagnosed by office hysteroscopy prior to in vitro fertilization. *Hum Reprod*.2010;**25**(8):1959-65
9. Hulka JF, Peterson HA, Phillips JM, Surrey MW. Operative hysteroscopy: American Association of Gynecologic Laparoscopists' 1993 membership survey. *J Am Assoc Gynecol Laparosc*.1995;**2**(2):131-2
10. Jansen FW, Vredevoogd CB, van Ulzen K, Hermans J, Trimbos JB, Trimbos-Kemper TC. Complications of hysteroscopy: a prospective, multicenter study. *Obstet Gynecol*.2000;**96**(2):266-70
11. Cayuela E, Cos R, Onbargi L, Moreno M, Mellado F, Heredia F, et al. Complications of operative hysteroscopy. *J American Asso Gynecologic Laparosc*.1996;**3**(4, Supplement 1):S6
12. Propst AM, Liberman RF, Harlow BL, Ginsburg ES. Complications of hysteroscopic surgery: predicting patients at risk. *Obst Gyn*.2000;**96**(4):517-520