



Minimally Invasive Technique for Removal of Giant Serous Cyst Adenoma of the Ovary

Nadine Hughes¹, Costa Healy¹, Anies Mahomed^{1*}

¹Department of Paediatric Surgery, Royal Alexandra Children's Hospital, Brighton, UK

ARTICLE INFO

Article type:
Case Report

Article history:
Received: 08 May 2012
Revised: 18 Jul 2012
Accepted: 27 Jul 2012

Keywords:
Ovarian Cysts
Child
Laparoscopy
Surgery

ABSTRACT

Background: Large ovarian cysts are rarely seen in the paediatric population and can now be managed by a variety of surgical approaches.

Case Presentation: We report a case where a substantial right ovarian cyst in a 13 year old was removed through a single incision in the superior umbilical fold leaving no discernable scar. The placement of a purse string facilitated safe decompression of the cyst allowing delivery into the wound where the lining was stripped before being returned to the abdomen.

Conclusions: Subsequent single incision laparoscopic surgery (SILS) port placement through the same wound allowed for a full inspection of the pelvis and abdomen. This approach represents an advance on conventional surgery and is a tenable alternative to an exclusive laparoscopic technique.

► Implication for health policy/practice/research/medical education:

We describe a simple method to manage large ovarian cysts. This is minimally invasive and safe. This approach can be considered for large ovarian cyst in children.

► Please cite this paper as:

Hughes N, Healy C, Mahomed A. Minimally Invasive Technique for Removal of Giant Serous Cyst Adenoma of the Ovary. *J Minim Invasive Surg Sci.* 2013;2(2):157-60. DOI: 10.5812/jmiss.6240

1. Background

Large ovarian cysts are rarely seen in the paediatric population. When encountered a dilemma on whether to proceed by open or the laparoscopic route might arise. The decision on the approach is complicated by a potential malignant risk in these cysts. The open approach, via Pfannensteil or midline laparotomy, affords excellent exposure and control, minimizing risk of cyst spillage. However, the requirement for a large incision for adequate access has distinct disadvantages. Alternatively, an exclusive laparoscopic approach while offering

excellent visualization with minimal trauma carries risk of cyst spillage with negative consequences. Reported is a minimalist technique which combines the benefits of both the above approaches.

2. Case Presentation

A 13 year old female patient was referred by her General Practitioner to the Children's Assessment Unit with right iliac fossa pain and vomiting. An abdominal ultrasound scan demonstrated a very large uniseptate and anechoic right ovarian cystic mass measuring 19 cm in

* Corresponding author: Anies Mahomed, Royal Alexandra Children's Hospital, Eastern Road, BN2 5BE, Brighton, UK. Tel.: +44-1273696955, Fax: +44-1273523120, E-mail: Anies.Mahomed@bsuh.nhs.uk

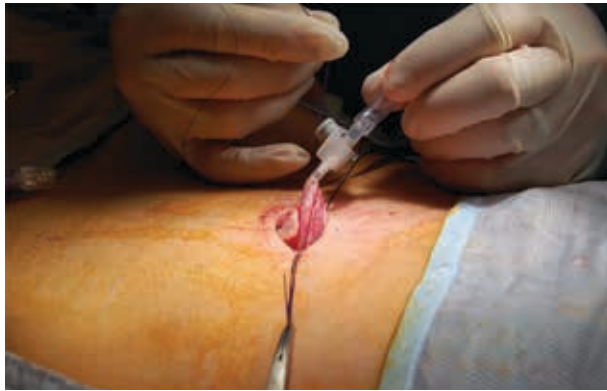DOI: 10.5812/jmiss.6240

© 2013 Minimally Invasive Surgery Research Center and Mediterranean & Middle Eastern Endoscopic Surgery Association.

This is an Open Access article distributed under the terms of the Creative Commons Attribution License (<http://creativecommons.org/licenses/by/3.0>), which permits unrestricted use, distribution, and reproduction in any medium, provided the original work is properly cited.

maximum diameter, extending above the umbilicus, and causing bilateral hydronephrosis. Tumour markers (alpha fetoprotein, beta HCG and CA 125) were negative. Consent was taken and arrangements made for a right ovarian cystectomy. An incision in the superior umbilical fold with a vertical division of linea alba were undertaken for access. The anterior wall of the cyst was immediately apparent under the wound and a purse string (3/0 vicryl) suture placed. Approximately 3L of serous fluid was aspirated via a large bore intravenous cannula connected to suction (*Figure 1*). Spillage of cyst content was avoided by maintaining tension on the stay suture. When decompressed, the cyst was delivered into the wound and the plane between mucosa and capsule developed until comprehensive enucleation of the lining was achieved (*Figure 2*). At this stage further traction on the cyst wall resulted in delivery of the left ovary which was inspected (*Figure 3*). Following reduction of the ovary and cyst outer wall, a single incision laparoscopic surgery (SILS) port (Covidean) was then placed in the wound enabling a comprehensive inspection of the opposite ovary, pelvic and abdominal contents. The

Figure 1. Drainage of the Serous Cystadenoma Using a Large Intravenous Cannula Attached to Suction



Stay suture in right hand controls any tendency to spillage. Sutures held on mosquito forceps are holding open the vertical incision in linea alba.

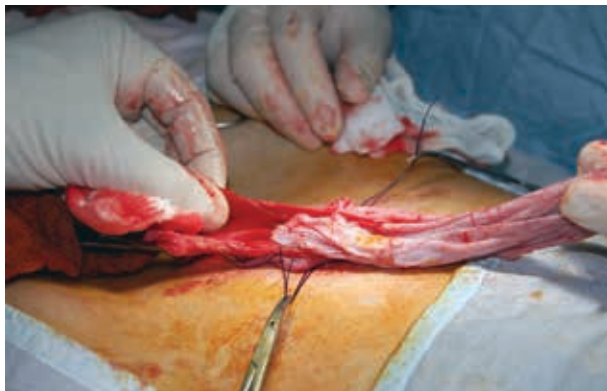


Figure 2. Comprehensive Enucleation Without Spillage of Cyst Content

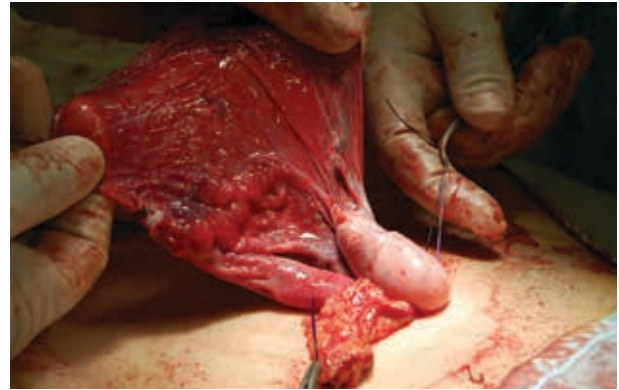

Figure 3. Delivery of the Right Ovary Into the Wound for Inspection

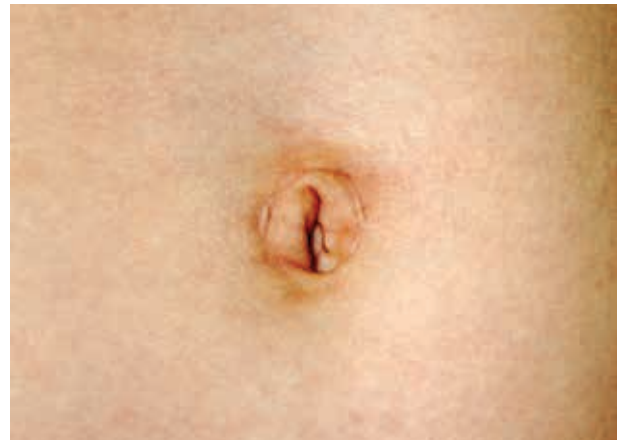

Figure 4. Final Aesthetic Outcome With Incision in Superior Umbilical Fold Barely Evident

wound was closed in layers leaving the umbilical profile intact (*Figure 4*). The patient was discharged the following day and a year later is in excellent health. Histology confirmed a benign serous cystadenoma and repeat ultrasonography has demonstrated resolution of the hydronephrosis.

3. Discussion

The vast majority of ovarian cysts in children are functional and are hormonally mediated. Surgical intervention for the majority of these is not required as spontaneous regression is expected. Surgery can be necessitated by persistence of the cysts, when symptomatic or when the cysts are greater than 5 cm in diameter or complex (1). Usually the physical characteristics can be elucidated by ultrasound scan, which as a non-invasive study can be repeated as needed to monitor any change in the nature and size of the cyst. The majority of simple ovarian cysts are benign and the recent trend has been to attempt to carry out ovarian sparing surgery. This can

be achieved by open or laparoscopic surgery and tends to preserve ovarian tissue. However, the risk of unheralded malignancy cannot be ignored and as such techniques which remove the entire lesion without rupture or spillage are needed. The potential risk of rupture during laparoscopic procedures needs to be minimized and the described technique in this case report seems a reliable approach. Malignant ovarian cysts are uncommon in the paediatric population, with only 4.5-16% of cysts being malignant (2). Sonography performed by experienced paediatric radiologists can aid with the histological diagnosis, however some ovarian malignancies can be documented as simple cysts without exhibiting a complex morphology (3). The advantages of laparoscopic procedures include the reduced wound size and evidently, need for wound healing that occur with open surgery. Cosmetically, the scars are less apparent and often represent the preferred approach of parents and children undergoing surgery. Minimally invasive surgery is a continually evolving field and the use of single incision laparoscopic surgery is being described for more and more procedures. The single incision which can be "hidden" within the umbilicus, represents a step forward in cosmesis following surgical procedures. Increasingly being recognized is the benefit of the expanded umbilical wound, which can be used to deliver mobile tissue for conventional surgical operations extracorporally. This has been used successfully for bowel resections and in this case, for enucleation of an ovarian cyst. This approach not only causes less trauma to the abdominal wall but also allows technically challenging surgery to be carried out under direct vision and without operating using laparoscopic instruments. Though laparoscopic skills and instruments are improving, the technical challenges of bowel anastomoses or precise intricate dissection remain easier and more reliable extracorporally. As the risk of malignancy is increased in large ovarian cysts, a laparotomy is traditionally undertaken to remove them for fear of seeding the cavity in the case of a malignant tumour. In this way, the cyst is kept intact and removed through a midline or Pfannenstiel incision. Indeed, there is a significant risk of cyst rupture associated with laparoscopy and therefore, laparotomy or laparoscopic-assisted extracorporeal cystectomy are recommended in large ovarian cysts (4). Our technique represents a variation on this technique which may represent an advance in extracorporeal cystectomy allowing the cyst stripping to be carried out meticulously under direct vision. Though laparoscopic pelvic surgery is considered a safe and effective method even in small infants (5, 6), large lesions in this age group cause additional challenges. In the adult population, management of ovarian cysts by laparoscopic surgery is clearly established and some authors advocate laparoscopic surgery even in the presence of very large cysts (7). However, this approach is not universal even

within the adult population where ovarian cysts are encountered much more frequently. The desire to carry out more technically challenging surgery by laparoscopic techniques is stimulated by a multitude of factors. Increasingly, there is patient demand for a cosmetically acceptable outcome, which minimizes scars. In addition to this, the reduced need for analgesia appeals to both clinicians and their patients. Multiple accounts have demonstrated reduced length of hospital stay which has benefits for the patients as well as maximizing the limited resources available. The benefits of reduced tissue trauma and scarring are further amplified in SILS, an appealing adaptation with purported better cosmetic results. SILS has been shown to be safe and effective in the paediatric population, even when using conventional laparoscopic instruments (8). The technical challenges of laparoscopic surgery can be amplified by the use of a single port. The trocars can become crowded and instruments may clash. These factors can be further amplified in children where the available cavity is smaller. When a large cyst is encountered these challenges combined with the laparoscopic risk of rupture make it very difficult to safely excise a very large ovarian cyst. Our technique provides a safe and a technically expeditious approach to giant ovarian cysts. The operation is done through a single intraumbilical incision, consequently reducing tissue trauma and scarring. The placement of a purse suture on the wall enabled stability and control of the cyst whilst suctioning its contents, eliminating the risk of spillage. The decompression of this cyst created sufficient mobility to allow the cyst to be delivered and enucleated through the umbilical incision with minimal difficulty, removing the need for more challenging laparoscopic surgery. It is also possible to deliver the involved ovary in order to undertake a detailed examination. Finally, following enucleation, it was possible to utilize the existing wound, without amendment to size for SILS port placement. This enabled excellent access for inspection of the opposite gonad and the rest of the pelvic and abdominal structures. Whilst reports of cyst enucleation with single incision laparoscopic surgery exist in the adult literature (9), they usually rely on intra-abdominal enucleation of the cyst with the inherent risk of rupture. We found a series of cases using standard laparoscopy to deliver the cyst to the umbilical port site as in our case. The authors emphasize the ease and safety of this approach. In addition, they cite similar strategies to our own in ensuring no spillage occurs (10). An earlier report describes utilizing a single 10 mm umbilical port with a much smaller 3 mm scope, thus allowing a working channel around the scope to grasp the ovarian cyst. This approach allowed delivery and aspiration of the cyst prior to resection (11). No mobilization of the cyst was needed in our case to present it to the umbilical wound. In addition, the advances made in SILS since this time allowed us to use the same wound to

thoroughly inspect the pelvis and contra lateral ovary without the need for secondary port site incisions.

4. Conclusions

We feel this approach is a safe, effective, simple method with limited tissue trauma resulting in an excellent aesthetic outcome. It combines the benefits of minimally invasive surgery with the safety and technical ease of open surgery, particularly important in ovarian cysts with an unknown histological status.

Acknowledgements

None declared.

Authors' Contribution

AM was responsible for the case and provided the technical report. NH prepared the initial draft which was expanded by CH. All authors have contributed to the final manuscript.

Financial Disclosure

None declared.

Funding/Support

None declared.

Reference

1. Kanizsai B, Orley J, Szigetvari I, Doszpod J. Ovarian cysts in children and adolescents: their occurrence, behavior, and management. *J Pediatr Adolesc Gynecol.* 1998;**11**(2):85-8.
2. Hernon M, McKenna J, Busby G, Sanders C, Garden A. The histology and management of ovarian cysts found in children and adolescents presenting to a children's hospital from 1991 to 2007: a call for more paediatric gynaecologists. *BJOG.* 2010;**117**(2):181-4.
3. Varras M. Benefits and limitations of ultrasonographic evaluation of uterine adnexal lesions in early detection of ovarian cancer. *Clin Exp Obstet Gynecol.* 2004;**31**(2):85-98.
4. Smorgick N, Barel O, Halperin R, Schneider D, Pansky M. Laparoscopic removal of adnexal cysts: is it possible to decrease inadvertent intraoperative rupture rate? *Am J Obstet Gynecol.* 2009;**200**(3):237 e1-3.
5. Aggarwal SK, Sinha SK, Ratan SK, Dhua A, Pant N, Borkar N, et al. Laparoscopic or laparoscopic-assisted pelvic surgery in small infants: our experience. *J Laparoendosc Adv Surg Tech A.* 2011;**21**(6):543-8.
6. Mahomed A, Jibril A, Youngson G. Laparoscopic management of a large ovarian cyst in the neonate. *Surg Endosc.* 1998;**12**(10):1272-4.
7. Sagiv R, Golan A, Glezerman M. Laparoscopic management of extremely large ovarian cysts. *Obstet Gynecol.* 2005;**105**(6):1319-22.
8. Tam YH, Lee KH, Sihoe JD, Chan KW, Cheung ST, Pang KK. Initial experience in children using conventional laparoscopic instruments in single-incision laparoscopic surgery. *J Pediatr Surg.* 2010;**45**(12):2381-5.
9. Fagotti A, Fanfani F, Marocco F, Rossitto C, Gallotta V, Scambia G. Laparoendoscopic single-site surgery (LESS) for ovarian cyst enucleation: report of first 3 cases. *Fertil Steril.* 2009;**92**(3):1168 e13-6.
10. Lee LC, Sheu BC, Chou LY, Huang SC, Chang DY, Chang WC. An easy new approach to the laparoscopic treatment of large adnexal cysts. *Minim Invasive Ther Allied Technol.* 2011;**20**(3):150-4.
11. Kosumi T, Kubota A, Usui N, Yamauchi K, Yamasaki M, Oyanagi H. Laparoscopic ovarian cystectomy using a single umbilical puncture method. *Surg Laparosc Endosc Percutan Tech.* 2001;**11**(1):63-5.