



Tension-Free Mesh Inguinal Hernia Repair; Laparoscopic or Open?

Mostafa Tolba¹, Ahmed Khairi^{1,2*}, Osman Nour-Eldin¹, Maher Salem¹, Ahmed Awad^{1,3}

¹ Department of Surgery, Dallah Hospital, Riyadh, Kingdom of Saudi Arabia

² Department of Surgery, Alexandria University, Cairo, Egypt

³ Department of Surgery, Ain-Shams University, Cairo, Egypt

ARTICLE INFO

Article type:
Research Article

Article history:
Received: 05 Sep 2012
Revised: 11 Nov 2012
Accepted: 17 Nov 2011

Keywords:
Hernia
Inguinal
Laparoscopy
Herniorrhaphy

ABSTRACT

Background: Laparoscopic tension-free repair of inguinal hernia was presented in 1990s, promising less pain and shorter recovery period.

Objectives: We have presented our experience on laparoscopic inguinal hernia tension-free repair and comparing it with the open one.

Patients and Methods: This is a retrospective study of cases undergone tension-free mesh inguinal hernia repair between July 2008 and October 2011. Cases were divided into two groups. Group I included cases that were repaired by the laparoscopic transabdominal preperitoneal (TAPP) approach and II by the open. Cases were compared regarding the operation time, the postoperative pain (early and long-term), the postoperative scrotal-related and wound complications and the recurrence as well as the cost.

Results: The study included 217 cases; 114 in the group I and 103 in the group II. The operation time was significantly longer in the TAPP group (76.5 ± 18 vs. 67.6 ± 20 minutes). However, the overall hospital stay was less (2.6 ± 0.79 vs. 2.9 ± 0.87 days.) Early postoperative pain scores in the groups I and II were 0.95 ± 1.36 and 1.48 ± 1.47 and long-term pain and numbness were 9% and 7.5% respectively, which were not significantly different between the two groups. The postoperative scrotal-related complications occurred more in the laparoscopic group (15% vs. 7.5%). Local wound complications were significantly more in the open technique (1.8% vs. 12%, groups I and II, respectively). Twelve (11%) cases in the group I undergone treatment of an incidentally discovered pathology during laparoscopy including; other side inguinal hernia (7), adhesions (4) and abdominal testis (1). The recurrence rates were 4.3% and 2.4% in the group I and II correspondingly.

Conclusions: Laparoscopic TAPP inguinal hernia repair has longer operation time and more cost than the open technique. Local wound complications were more prevalent in the open repair. The postoperative pain, the hospital stay, the scrotal-related complications as well as the recurrence rates were the same in the both groups. The laparoscopy can detect and treat other intra-abdominal pathologies which have not been diagnosed preoperatively.

► Implication for health policy/practice/research/medical education:

The manuscript presents our experience on the tension-free inguinal hernia repair technique. We have tried to make some consensus for the choice of approach

► Please cite this paper as:

Tolba M, Khairi A, Nour-Eldin O, Salem M, Awad A. Tension-Free Mesh Inguinal Hernia Repair; Laparoscopic or Open? *J Minim Invasive Surg Sci.* 2013; 2(2): 149-53. DOI: 10.5812/jmiss.7633

* Corresponding author: Ahmed Khairi, Department of Surgery, Dallah Hospital, P.O. Box: 87833, Riyadh, Kingdom of Saudi Arabia. Tel: +966-508122154, Fax: +966-14702240, E-mail: ahmedkhairi@hotmail.com

DOI: 10.5812/jmiss.7633

© 2013 Minimally Invasive Surgery Research Center and Mediterranean & Middle Eastern Endoscopic Surgery Association.

This is an Open Access article distributed under the terms of the Creative Commons Attribution License (<http://creativecommons.org/licenses/by/3.0>), which permits unrestricted use, distribution, and reproduction in any medium, provided the original work is properly cited.

1. Background

In 1984, Lichtenstein *et al* coined the term “Tension-Free Hernioplasty” and advocated routine use of mesh for hernia repair (1). Laparoscopic Tension-Free repair was presented in 1990s, promising less pain and shorter recovery period (2, 3).

2. Objectives

We have presented our experience on the laparoscopic tension-free inguinal hernia repair and comparing it with the open technique.

3. Patients and Methods

This is a retrospective study of cases undergone tension-free mesh inguinal hernia repair performed between July 2008 and October 2011. Cases were divided into two groups. Group I included cases that were treated by the laparoscopic transabdominal preperitoneal (TAPP) approach (4) and II by the open approach (1). Cases were compared regarding the operation time, the postoperative pain (early and long-term), the postoperative scrotal-related and wound complications and the recurrence as well as the cost. Exclusion criteria were cases of recurrent, strangulated hernias as well as cases performed under local anesthesia due to old age or comorbid medical problems. Data was represented as mean \pm SD where appropriate. The differences between the two groups were determined by Chi-square test for categorical variables and the student t-test for continuous scale variables. P value less than 0.05 was considered as significant.

4. Results

The study included 217 cases, 114 in the group I and 103 in the group II. The age ranged between 22 and 75 years (mean 45.8) in the group I and between 14 and 91 (mean 45.6) in the group II. The hernia was on the right side in 50 (44%) cases of group I and 51 (50%) of group II, while it was on the left side in 49 (43%) cases of group I and in 47

(47%) of group II, and bilateral in 15 (13%) cases of group I and 5 (3%) of group II. In the group I, 10 cases (8.7%) were converted to open repair, 6 cases (5.5%) had repair of another preoperatively diagnosed hernia (3 paraumbilical and 3 femoral) and 12 cases (11%) undergone treatment of another incidentally discovered lesion during laparoscopy (7 other side inguinal hernia, 4 release of abdominal adhesions and 1 abdominal testis). Two cases in the group I had urinary bladder injury during the repair of bilateral inguinal hernias. On postoperative ascending cystogram, mild intraperitoneal extravasation of the dye was shown (Figure 2). Both cases were managed conservatively by simple bladder drainage for 7 days. Cases were followed up for 8 to 36 months (mean = 22). Table 1 summarizes the results.

5. Discussion

Nyhus has stated in his book entitled Hernia that “The history of hernia repair is the history of surgery” (5). Herniorrhaphy is the second prevalent operation after appendectomy in general surgery (6). The standard method for inguinal hernia repair had been changed little over a hundred years until the introduction of synthetic mesh. This mesh can be placed by either an open or a minimally invasive endoscopic technique. The most common endoscopic techniques are transabdominal preperitoneal (TAPP) and totally extraperitoneal (TEP) approaches. In TAPP (4), the surgeon goes into the peritoneal cavity with laparoscopic approach and places a mesh through a peritoneal incision over possible hernia sites (Figures 1A-E). TEP (7) is different as the peritoneal cavity is not entered and mesh is used to seal the hernia from outside the peritoneum. The authors routinely use the TAPP technique which has been compared to the open one. In our study, the operation time was longer in the TAPP group compared to the open group (76.5 \pm 18 vs. 67.6 \pm 20 minutes; $P = 0.02$; significant). However, the overall hospital stay was less (2.6 \pm 0.79 vs. 2.9 \pm 0.87 days; P value insignificant). Despite many advances made in TAPP technique, still the

Table 1. Tension-Free Mesh Inguinal Hernia Repair in Laparoscopic Transabdominal Preperitoneal TAPP Versus Open Techniques

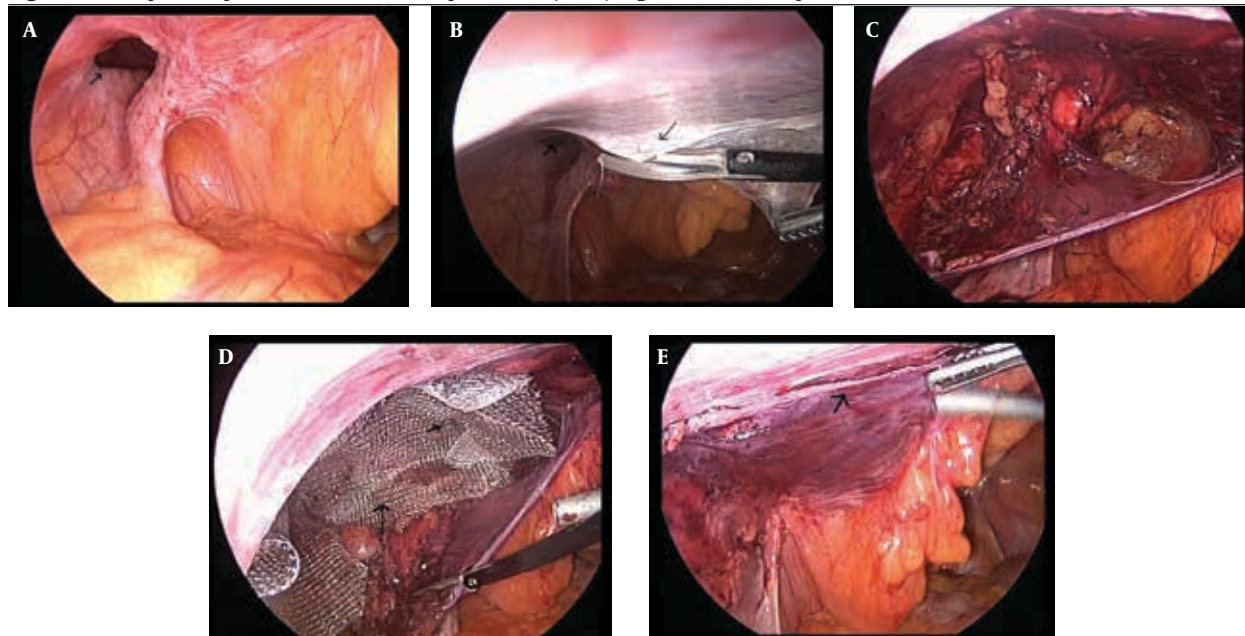
| | Group I (TAPP) (n = 114) | Group II (open) (n = 103) | P value |
|---|--------------------------|---------------------------|--------------------|
| Operative time, min, Mean \pm SD | 76.5 \pm 18 | 67.6 \pm 20 | 0.024 ^a |
| Hospital stay, d, Mean \pm SD | 2.6 \pm 0.79 | 2.9 \pm 0.87 | 0.08 |
| Postoperative pain score ^b , Mean \pm SD | 0.95 \pm 1.36 | 1.48 \pm 1.47 | 0.06 |
| Cost ^c | 12000 | 6500 | |
| Postoperative scrotal complications, No. (%) | 17 (15) | 8 (7.5) | 0.17 |
| Local wound complications, No. (%) | 2 (1.8) | 12 (12) | 0.036 ^a |
| Recurrence, No. (%) | 5 (4.3) | 3 (2.4) | 0.53 |
| Persisting pain & numbness after one month, No. (%) | 10 (9) | 8 (7.5) | 0.81 |

Abbreviation: TAPP, transabdominal preperitoneal

^a $P =$ Significant

^b First 48 hours

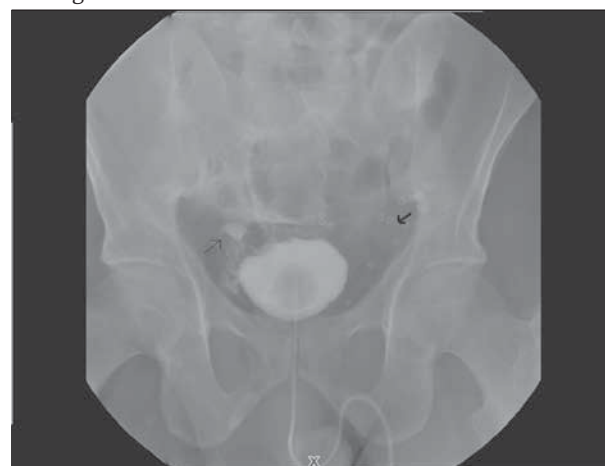^c Saudi Rls

Figure 1A-E. Laparoscopic Transabdominal Preperitoneal (TAPP) Inguinal Hernia Repair

A) Left inguinal hernia; widely open deep ring (arrow), B) Starting the peritoneal flap dissection (thin arrow) away from the deep ring (thick arrow), C) The peritoneal flap dissection is completed (arrow), D) The mesh is placed in the dissected preperitoneal plane over the area of the defect. Note one of the "tuckers" used for mesh fixation (arrow), E) The peritoneal flap overlapping the mesh

operative duration is longer. Although the time needed for the dissection of the peritoneal flap and tucking the mesh in its place have become less with more practice, the time required to assemble the laparoscope, create the pneumoperitoneum, insert the ports have remained the same. There are some reports of serious complications as visceral, mainly urinary bladder and vascular injuries during laparoscopic inguinal hernia repairs (8, 9). However, it can be avoided with proper identification of the anatomical landmarks during the dissection of the peritoneal flap together with great care during applying the «tuckers» and keeping away from the area of the big vessels (triangle of doom). We always keep the bladder empty during the procedure by asking patient to empty his bladder preoperatively as well as by intraoperative catheterization if needed. Despite of this, in two cases (1.8%), with bilateral inguinal hernia repaired with laparoscopic approach, urinary bladder injury was occurred (Figure 2). In both cases, this was treated by simple catheter drainage for 7 days without any need for intervention. Early postoperative pain was the same in both groups. The Faces Pain Rating Scale (10) was 0.95 ± 1.36 and 1.48 ± 1.47 in the groups I and II respectively (*P* value is non-significant). This could be partly explained by the fact that we routinely use local infiltration anesthesia in wounds for open repair. However, over the following 2 to 3 weeks after hospital discharge, and although not well documented in the study, we observed less complaints of pain in the laparoscopic group and less need for analgesics

compared to the open group. Long-term inguinal neuralgia due to nerve entrapment was reported to occur in up to 20% following open repair (11). Laparoscopic repair also puts several nerves at the risk of entrapment. Mesh fixation may be the etiology of postoperative pain. Some surgeons advocated placing the mesh without fixation in the preperitoneal space to avoid nerve injury. It is argued

Figure 2. Bladder Injury After Laparoscopic TAPP Repair of Bilateral Inguinal Hernia

Note the dye leak in the cystogram (thin arrow) and the tuckers of mesh fixation on both sides (thick arrow). This patient was treated by simple bladder transurethral catheter drainage for 7 days. No intervention was needed.

that large size meshes don't need fixation and will prevent recurrence (12). In our study, also the persisting pain and numbness were not different between the two groups (9% and 7.5% in the groups I and II respectively, P value is non-significant). We did not comment on the time required to return to work. We believe that this would not reflect only the postoperative pain, as many other factors would have a role, whether social or related to the work circumstances. For example, a patient with a job that entails heavy lifting might need a much longer time away from work than someone who sits at a desk. Some patients might receive their payments during sick leave, so they are less likely to go back to work. Ischemic orchitis occurs in 2% to 3% of herniorrhaphies (13). Although it seems less in laparoscopic approach (14). In our study the postoperative scrotal-related complications (edema, orchitis or hydrocele) were more in the laparoscopic group (15%) than the open (7.5%) (P value is non-significant). Interruption of the cord lymphatics at the area of the deep inguinal ring was probably the main reason. Except for two cases that required hydrocelectomy few months later, all the other cases resolved spontaneously with simple scrotal support and anti-inflammatory medications. With more experience and more delicate dissection at this area, these complications could be reduced. We also noticed that more patients would accept some scrotal swelling postoperatively in the open technique, having a wound in the area, than in the laparoscopy. Some studies compared the recurrence rates of inguinal hernia following Shouldice (non-mesh), Lichtenstein (open mesh) and the TAPP repairs and found a higher rate in the first approach than the two others (15). They concluded that reduced hernia recurrence was related to the use of the mesh rather than the method of mesh placement. However, a big clinical trial involving 2164 patients from 14 centers found that the recurrence rate was higher in the laparoscopic group than the open group (10.1% vs. 4.1% respectively) (16). However, further detailed review of the same study demonstrated that experienced surgeons who had performed more laparoscopic repairs had only a 5% recurrence rate which shows learning curve role. We routinely use mesh for the repair whether in laparoscopy or open approaches. The relatively low recurrence rates in our study (4.3% and 2.4% in groups I and II respectively) are probably due to the relatively small number of our sample size as well as the relatively short follow up period (8-36 months; mean = 22). With longer follow up, the recurrence rate may show some changes. Still proper identification of anatomical landmarks together with the ability to identify areas of weakness during laparoscopy even before clinically present as hernia are essential to minimize the recurrence rates. Seven cases (6%) in group I undergone treatment of an incidentally discovered other side inguinal hernia during laparoscopy. Local wound complications (bruises and infection) were

statistically significant in the open group ($P = 0.03$). Two cases in the laparoscopy group had chronic pain at the site of umbilical port which improved with analgesics. The National Institute of Clinical Excellence (NICE) recommends the laparoscopic approach only for bilateral or recurrent hernia (17). Our study did not show any significant difference between the both groups regarding the postoperative pain, the hospital stay, the scrotal-related complications and the recurrence rates. However, Laparoscopy enabled the surgeon to inspect both groins for a potential hernia which was not clinically diagnosed and could detect other intra-abdominal pathologies as well. Although the open repair had significantly more local wound complications than laparoscopy, but it was cheaper with less operative time.

Acknowledgements

None Declared.

Authors' Contribution

None declared.

Financial Disclosure

None Declared.

Funding Support

None Declared.

References

1. Lichtenstein IL, Shulman AG. Ambulatory outpatient hernia surgery. Including a new concept, introducing tension-free repair. *Int Surg*. 1986;71(1):1-4.
2. Liem MS, van der Graaf Y, van Steensel CJ, Boelhouwer RU, Clevvers GJ, Meijer WS, et al. Comparison of conventional anterior surgery and laparoscopic surgery for inguinal-hernia repair. *N Engl J Med*. 1997;336(22):1541-7.
3. Stoker DL, Spiegelhalter DJ, Singh R, Wellwood JM. Laparoscopic versus open inguinal hernia repair: randomised prospective trial. *Lancet*. 1994;343(8908):1243-5.
4. Bittner R, Schmedt CG, Schwarz J, Kraft K, Leibl BJ. Laparoscopic transperitoneal procedure for routine repair of groin hernia. *Br J Surg*. 2002;89(8):1062-6.
5. Nyhus LM, Condon RE. *Hernia*. 4th ed. Philadelphia: Lippincott; 1995.
6. Grunwaldt LJ, Schwaizberg SD, Rattner DW, Jones DB. Is laparoscopic inguinal hernia repair an operation of the past? *J Am Coll Surg*. 2005;200(4):616-20.
7. Bringman S, Ramel S, Heikkinen TJ, Englund T, Westman B, Anderberg B. Tension-free inguinal hernia repair: TEP versus mesh-plug versus Lichtenstein: a prospective randomized controlled trial. *Ann Surg*. 2003;237(1):142-7.
8. Edwards CC, 2nd, Bailey RW. Laparoscopic hernia repair: the learning curve. *Surg Laparosc Endosc Percutan Tech*. 2000;10(3):149-53.
9. Pokorny H, Klingler A, Schmid T, Fortelny R, Hollinsky C, Kawji R, et al. Recurrence and complications after laparoscopic versus open inguinal hernia repair: results of a prospective randomized multicenter trial. *Hernia*. 2008;12(4):385-9.
10. Scale: W-BFR. Wong's Essentials of Pediatric Nursing In: Wong DL, Hockenberry-Eaton M, Wilson D, Winkelstein ML, Schwartz P, eds, editors.: St. Louis; 2001. p. 1301.

11. Stephenson BM. Complications of open groin hernia repairs. *Surg Clin North Am.* 2003;**83**(5):1255-78.
12. Stoppa RE. The treatment of complicated groin and incisional hernias. *World J Surg.* 1989;**13**(5):545-54.
13. Pollak R, Nyhus LM. Complications of groin hernia repair. *Surg Clin North Am.* 1983;**63**(6):1363-71.
14. Fitzgibbons RJ, Jr., Camps J, Cornet DA, Nguyen NX, Litke BS, Annibaldi R, et al. Laparoscopic inguinal herniorrhaphy. Results of a multicenter trial. *Ann Surg.* 1995;**221**(1):3-13.
15. Butters M, Redecke J, Koninger J. Long-term results of a randomized clinical trial of Shouldice, Lichtenstein and transabdominal preperitoneal hernia repairs. *Br J Surg.* 2007;**94**(5):562-5.
16. Neumayer L, Giobbie-Hurder A, Jonasson O, Fitzgibbons R, Jr., Dunlop D, Gibbs J, et al. Open mesh versus laparoscopic mesh repair of inguinal hernia. *N Engl J Med.* 2004;**350**(18):1819-27.
17. Bloor K, Freemantle N, Khadjesari Z, Maynard A. Impact of NICE guidance on laparoscopic surgery for inguinal hernias: analysis of interrupted time series. *BMJ.* 2003;**326**(7389):578.