



## Laparoscopic Management of Omental Cyst in a Child Using Two Ports Technique: A Case Report and Review of Relevant Literature

Rahul Kumar Gupta<sup>1\*</sup>, Paras Kothari<sup>1</sup>, Abhay Gupta<sup>1</sup>, Ritesh Ranjan<sup>1</sup>, Krushna Kumar Kesan<sup>1</sup>, Kedar Mudkhedkar<sup>1</sup>, Niyaz Mohammed<sup>1</sup>, Parag Karkare<sup>1</sup>

<sup>1</sup>Department of Pediatric Surgery, Lokmanya Tilak Municipal Medical College and Lokmanya Tilak Municipal General Hospital (LTMMC and LTMGH), Sion Mumbai, India

### ARTICLE INFO

*Article type:*  
Case Report

*Article history:*  
Received: 25 Nov 2011  
Revised: 27 Mar 2012  
Accepted: 22 July 2012

*Keywords:*  
Laparoscopy  
Omentum  
Cysts  
Pediatrics

### ABSTRACT

**Background:** Omental cysts are rarely intra-abdominal pathology. We report a case of omental cyst successfully resected by laparoscopy using two ports only with excellent outcome.

**Case Presentation:** Our patient was a seven year old girl who presented with complaints of lump in abdomen, in which laparoscopy aided in making a correct final diagnosis and the surgical management. Preoperative diagnostic work-up included Ultrasonography and Computed Tomography scan (CT scan) of abdomen which revealed huge intra-abdominal cystic lesion of unknown origin. Extensive diagnostic workup did not reveal the etiology of his problem. Diagnostic laparoscopy led to the correct diagnosis and appropriate surgical treatment with complete relief of his complaint. Histopathology of the excised specimen was suggestive of lymphangioma.

**Conclusions:** On six months of follow up, the patient is doing well and asymptomatic with no evidence of recurrence.

### ► Implication for health policy/practice/research/medical education:

In present era we are trying to reduce number of scars on patient's body. Our case report is another step towards it. With the development of laparoscopy in the last decade, laparoscopic surgery has come to be preferred to laparotomy because it may result in less post-operative pain and analgesics, a shorter hospital day, and earlier return to normal activity. No different post-operative complications occur between laparotomy and laparoscopy.

### ► Please cite this paper as:

Gupta RK, Kothari P, Gupta A, Ranjan R, Kesan KK, Mudkhedkar K, et al. Laparoscopic Management of Omental Cyst in a Child Using Two Ports Technique: A Case Report and Review of Relevant Literature. *J Minim Invasive Surg Sci.* 2013; 2(1): 111-5. DOI: 10.5812/jmiss.3615

## 1. Background

Omental cysts have a prevalence of 1:1,000,000 in adults and in 1:20,000 in children (1). They are rarely intra-abdominal lesions arising due to benign proliferations of sequestered lymphatic tissue which do not have communication with the lymphatic system. They have unclear

pathogenesis (2, 3). The terms, mesenteric and omental cysts, defines site of origin and gross appearance rather than pathological diagnosis. Omental cysts arises from either lesser or greater omentum while mesenteric cyst can located anywhere along the length of mesentery of gastrointestinal tract (2, 4). Over the last few years minimal access surgical techniques have been evolved and

\* Corresponding author: Rahul Kumar Gupta, Department of Pediatric Surgery, Lokmanya Tilak Municipal Medical College and Lokmanya Tilak Municipal General Hospital (LTMMC and LTMG Hospital), Sion, Mumbai, Maharashtra, India. Tel: +91-9833112941, Fax: +91-2224107000, E-mail: drrahul78@yahoo.co.in

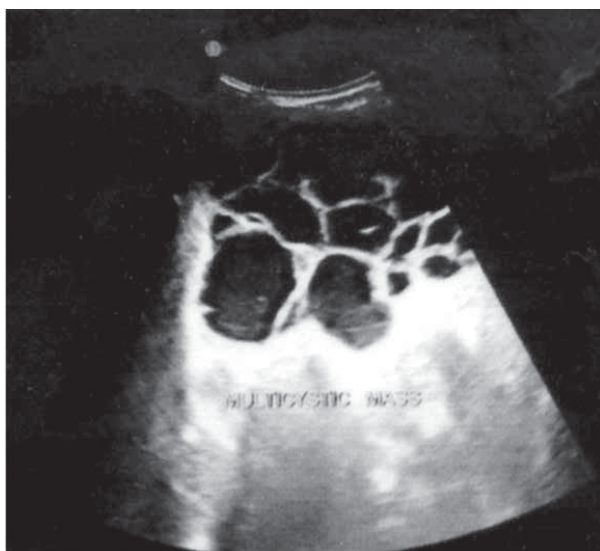
DOI: 10.5812/jmiss.3615

Copyright © 2013, Minimally Invasive Surgery Research Center and Mediterranean & Middle Eastern Endoscopic Surgery Association. This is an open-access article distributed under the terms of the Creative Commons Attribution License, which permits unrestricted use, distribution, and reproduction in any medium, provided the original work is properly cited.

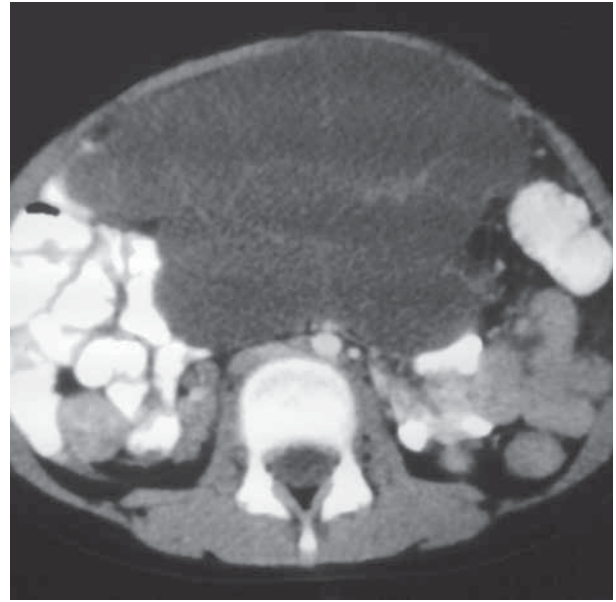
used to manage various surgical conditions not only in adults but also in pediatrics. Benign lesions such as mesenteric and omental cysts would appear to be ideally suited to this approach. First, laparoscopic excision of a large mesenteric cyst was performed by Mackenzie in 1993, demonstrating the feasibility and safety of the laparoscopic technique (5). In this study, we report a case of an omental cyst which was successfully managed by laparoscopy using two ports only along with review of relevant literature.

## 2. Case Presentation

A seven year old girl was brought by her parents to us as they noticed a swelling in her lower abdomen 15 days back. According to them, the lump was initially small but later on gradually increased in size. There was no history of pain, constipation, fever, vomiting, bleeding per rectum or trauma. There was no history of Koch's contact, loss of weight or loss of appetite. Bladder and bowel history was normal. On examination, she had average built and pallor was present. On abdominal examination, a well-defined non-tender lump, of size  $10 \times 8 \times 6$  cm, was palpable in central part of the abdomen. It was freely mobile in all directions and was cystic in consistency. Rest of the systemic examination was normal. Her complete blood profile, renal function tests and liver function tests were within normal limits. Her tumor markers, alpha-fetoprotein (1.83 IU/mL) and beta-HCG ( $< 1.2$  mIU/mL), were also within normal limit. Her X-ray erect abdomen showed a soft tissue shadow in central part of the abdomen surrounded by gas filled bowel loops. Her Ultrasound abdomen showed a large multicystic mass in the pelvis extending up to mid part of abdomen. It wasn't clear whether it is the sign of loculated ascites, or cystic mass in pel-

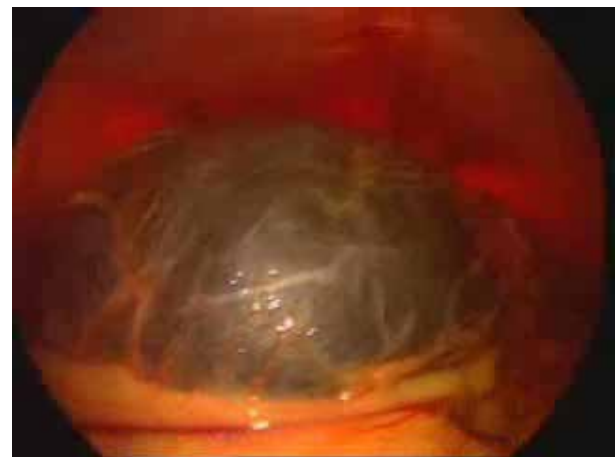

**Figure 1.** Ultrasound Abdomen Showing a Large Multicystic Mass in the Pelvis Extending up to Mid-part of Abdomen



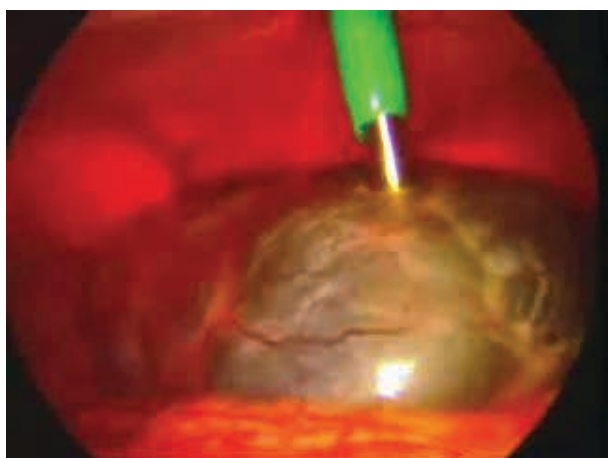
**Figure 2.** Computed Tomography Scan of Abdomen Showing a Large Multiseptated Cystic Lesion in the Pelvis and Lower Abdomen

vis (Figure 1). Computed Tomography scan (CT scan) of abdomen showed a large multiseptated cystic lesion in the pelvis and lower abdomen with mass effect on the surrounding bowel loops, bilateral common iliac vessels and bilateral ureters mostly lymphangioma rather than ovarian lesion (Figure 2). With above findings, we

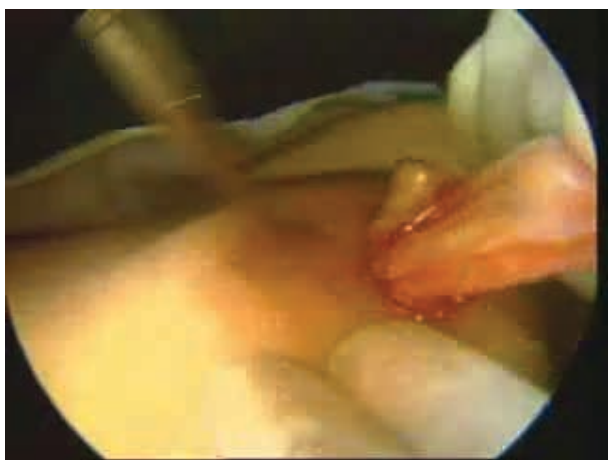

**Figure 3.** Showing a Large Multiloculated Cystic Lesion Involving Omentum

decided to perform diagnostic laparoscopy. A 5 mm epigastric port was inserted as camera port. A large multiloculated lesion involving omentum was noted (Figure 3). Another 5 mm working port was inserted in the umbilical region and lesion was decompressed using suction aspiration needle (Figure 4). The lesion was delivered out through umbilical port (Figure 5) and



**Figure 4.** Showing Lesion Being Aspirated Using Suction Aspiration Needle



**Figure 5.** Showing Lesion Being Delivered out Through Umbilical Port

was completely excised. Patient was started on liquid diet in the evening and was discharged on next morning. Histopathology of the excised specimen was suggestive of lymphangioma. On six months follow up, patient is doing well and asymptomatic with no evidence of recurrence.

### 3. Discussion

Grairdner recorded the first report of an omental cyst, which is one third as common as mesenteric cyst in 1852 (3). There are only about 100 cases reported in the literature till date (6) one third of which occur in children younger than 15 years (7, 8) and were having male to female ratio of 1:1. Various theories proposed to explain etiopathogenesis of omental cysts are as follows:

- Benign proliferation of ectopic lymphatics that lack communication with the normal lymphatic system (9).
- Lymphatic obstruction (9, 10).
- Failure of the embryonic lymph channels to join the venous system.

- Post-traumatic.
- Neoplastic.
- Secondary to degeneration of lymph node.

In 2000, Marc de Perrot, proposed this more comprehensive, six-group classification based on the histological identity of the epithelial lining when present (11):

- Lymphatic cysts (simple lymphatic cyst and lymphangioma).
- Mesothelial cysts (simple mesothelial cyst, benign cystic mesothelioma, and malignant cystic mesothelioma).
- Enteric cysts (including enteric duplication cyst).
- Urogenital cysts.
- Mature cystic teratoma (dermoid cysts).
- Pseudocysts (infectious and traumatic cysts).

Omental cysts can be simple or multiple, unilocular or multilocular, and they contain serous or chylous fluid, but can be bloody (hemorrhage into the cyst). They range in sizes from few millimeters to a mass involving the entire abdomen. The patients of omental cysts either can remain asymptomatic or can present with acute or chronic abdominal pain. Forty percent of cases are detected incidentally while patient is undergoing physical examination, radiological examination, or abdominal surgery due to other causes (1). Most commonly children present with both chronic abdominal distension and pain or with symptoms secondary to mass effect of large size lesion on gastrointestinal and genitourinary system. Sometimes the mass may be of so large size that it can mimic ascites. Acute presentations such as small bowel obstruction, torsion of cyst pedicle, intracystic hemorrhage, infection or rupture into the abdominal cavity are more common in cases of mesenteric cyst (66%) (8) than that of omental cysts (10%) (12, 13). The reported incidence of malignant conditions (sarcoma, lymphangioendothelioma, or, rarely, adenocarcinoma) is 3% (13), but no malignant mesenteric or omental cysts have been reported in children. On physical examination, a smooth, round and compressible abdominal mass is the most common finding. Omental cysts can be moved freely in all directions while mesenteric cysts have free movement only horizontally but have restricted movement vertically. There is no single confirmatory diagnostic test. X-ray abdomen can show ground glass appearance suggestive of pseudoascites or intra-abdominal fluid. Ultrasonography and/or CT scans can show variable features suggestive of liquid content, regular margins, and capsule integrity with no vascular abnormalities, but unable to suggest accurate diagnosis. Magnetic resonance imaging (MRI) can be more useful in comparison to CT scan as it has less radiation exposure risk. It was not done in our case as facility for pediatric anesthesia was not available in our radiology department and it was not possible to sedate her. Cystic lymphangiomas are simple cysts with an endothelial cell lining, foam cells, and thin walls that contain small

lymphatic spaces, lymphoid tissue, and smooth muscle. The wall of a mesenteric cyst lacks smooth muscle and lymphatic spaces, and the lining cells are cuboidal or columnar (2). Lymphangiomas occur in the mesentery or retroperitoneum and tend to present early in life with acute abdominal symptoms, whereas mesenteric cysts are limited to the mesentery and present in adulthood as asymptomatic masses (2). There is a big difference between a mesenteric cyst and a cystic lymphangioma. It is important for the prognosis, because when there is a cystic lymphangioma with an incomplete resection, one has the danger of a recurrence with tendency to invasive growth. Other differential diagnosis includes tubercular ascites and, cystic mesothelioma. In case of unclear diagnosis or tubercular ascites the risk of injury of the tissue and contamination without protection of umbilicus during the dissection and extirpation through the umbilicus is very high. In those cases a protection is necessary such as a Triport® or other protection. Definitive treatment of omental cyst is complete surgical resection. Cyst enucleation and complete excision can be done safely because these cysts are not connected with any normal structure except for loose tissue. For complete excision, bowel resection is rarely needed in case of omental cyst in comparison with those of mesenteric cysts (50-60%) (7, 8, 12, 13). First complete laparoscopic excision of a mesenteric cyst was described by Mackenzie in 1993 (4). In few cases, it can be difficult to dissect omental cysts safely from surrounding tissues without bowel or vessel injury because of wide attachment of stalk of the omentum to the cyst, which can lead to serious bleeding and injuries to the surrounding stomach or intestines while dissection. Resection of the large size omental cyst can lead to significant bleeding because omentum derives its blood supply from celiac trunk (major artery) through gastro-omental arteries (14). For this type of cases, the twisting of the cyst at the base of the omental stalk (to convert a broad base of the cyst to narrow band-like structure so that it can be cut easily by bipolar forceps, followed by unipolar forceps) can be used to prevent significant bleeding. It is very necessary to completely excise intact cyst due to high incident of relapse and infection after aspiration, marsupialization or unroofing of the omental cyst (7). There are reports available of relapse after laparoscopic unroofing. The mortality rate of the open procedure varies from 0% to 8% (maximum of 15% in cases involving intestinal resection) (1). It is not possible to evaluate morbidity and mortality rate of laparoscopic surgery for omental cyst as only 13 cases have been reported till date with no death or complications. The unique feature of our case is that we used two port technique for laparoscopic excision of omental cyst (epigastric port as telescopic port and umbilical port for decompression and excision) while three ports were used in all previously reported cases. There are various reports available of use of transumbilical two

ports through the single umbilical incision for management of ovarian cyst (15) and renal cyst (16) but none is available for management of omental cyst. We used epigastric port instead of transumbilical single incision two port approach due to presence of lump in umbilical region as we were not sure about the diagnosis preoperatively. After that we used umbilical port. The disadvantage of single incision two port technique is crowding of instruments (chop stick effect) which are not there in our technique. Our technique also has certain limitations. Our technique is useful in selected case where omental cyst is unilocular and not adhered to mesentery or bowel or any surrounding structures as dissection is not possible with single working port. Another limitation of our technique is risk of spillage of cyst content. As we are using single working port we need to be cautious to prevent omental vessels damage following, otherwise it would be difficult to control bleeding.

#### 4. Conclusions

With the development of laparoscopy in the last decade, laparoscopic surgery has come to be preferred to laparotomy because it may result in less post-operative pain and analgesics, a shorter hospital day, and earlier return to normal activity. No different post-operative complications occur between laparotomy and laparoscopy. Omental cysts can be removed safely via laparoscopy using two ports only without bowel or vessel injury.

#### Acknowledgments

None declared.

#### Authors' Contribution

None declared.

#### Financial Disclosure

None declared.

#### Funding/Support

None declared.

#### References

1. Theodoridis TD, Zepiridis L, Athanatos D, Tzeveleakis F, Kellartzis D, Bontis JN. Laparoscopic management of mesenteric cyst: a case report. *Cases J.* 2009;2:132.
2. Takiff H, Calabria R, Yin L, Stabile BE. Mesenteric cysts and intra-abdominal cystic lymphangiomas. *Arch Surg.* 1985;120(11):1266-9.
3. Vanek VW, Phillips AK. Retroperitoneal, mesenteric, and omental cysts. *Arch Surg.* 1984;119(7):838-42.
4. Egozi EI, Ricketts RR. Mesenteric and omental cysts in children. *Am Surg.* 1997;63(3):287-90.
5. Mackenzie DJ, Shapiro SJ, Gordon LA, Ress R. Laparoscopic excision of a mesenteric cyst. *J Laparosc Surg.* 1993;3(3):295-9.
6. Tillaux P. [Cyst du mesentere un home: ablation par la gastromie: quersion]. *Revue de therapeutiques Medico chirurgicale.*

- 1880;47:479.
7. Brentano L, Faccini P, Oderich GS. Laparoscopic resection of a mesenteric cyst. *Surg Laparosc Endosc.* 1998;8(5):402-3.
  8. Kurtz RJ, Heimann TM, Holt J, Beck AR. Mesenteric and retroperitoneal cysts. *Ann Surg.* 1986;203(1):109-12.
  9. Bliss DP, Jr., Coffin CM, Bower RJ, Stockmann PT, Ternberg JL. Mesenteric cysts in children. *Surgery.* 1994;115(5):571-7.
  10. Alqahtani A, Nguyen LT, Flageole H, Shaw K, Laberge JM. 25 years' experience with lymphangiomas in children. *J Pediatr Surg.* 1999;34(7):1164-8.
  11. de Perrot M, Brundler M, Totsch M, Mentha G, Morel P. Mesenteric cysts. Toward less confusion? *Dig Surg.* 2000;17(4):323-8.
  12. Lawrence RA, Putnam TC, Webb SR. Omental cyst: presentation in an infant with jaundice and increasing abdominal girth. *J Pediatr Gastroenterol Nutr.* 1992;15(1):97-9.
  13. Mollitt DL, Ballantine TV, Grosfeld JL. Mesenteric cysts in infancy and childhood. *Surg Gynecol Obstet.* 1978;147(2):182-4.
  14. Youn Seung O, Song Yee H, Bo Ryoung H, Ki Hoon A, Hyun Tai P, Jae Yun S, et al. Laparoscopic treatment of an omental cyst misdiagnosed as an adnexal cyst: A case report. *J Womens Med.* 2010;3(2):84-7.
  15. Visnjic S, Domljan M, Zupancic B. Two-port laparoscopic management of an autoamputated ovarian cyst in a newborn. *J Minim Invasive Gynecol.* 2008;15(3):366-9.
  16. Al Dowais A, Samei H. First case report of totally trans-umbilical laparoscopic de-roofing of large renal cyst with "Najran technique". *Internet J Surg.* 2009;21(2).