

A Prospective Randomized Trial to Study The Effect of Intraperitoneal Instillation of Ropivacaine in Postoperative Pain Reduction in Laparoscopic Cholecystectomy

Pankaj Shivhare¹; Pankaj Dugg^{1*}; Harnam Singh²; Sushil Mittal²; Ashwani Kumar²; Anand Munghate²

¹Department of Surgery, All India Institute of Medical Sciences, New Delhi, India

²Department of General Surgery, Government Medical College, Patiala, India

*Corresponding author: Pankaj Dugg, Department of Surgery, All India Institute of Medical Sciences, New Delhi, India. Tel: +91-9417388800, Fax: +91-1812651306, E-mail: dr_dugg@rediffmail.com

Received: February 3, 2014; Revised: June 17, 2014; Accepted: July 15, 2014

Background: Postoperative pain following laparoscopic cholecystectomy can be due to various reasons. In this study reduction of visceral and shoulder tip pain is studied with intra peritoneal instillation of ropivacaine.

Objectives: The study was done to see the effect of intraperitoneal instillation of ropivacaine on postoperative abdominal pain and shoulder pain in laparoscopic cholecystectomy.

Patients and Methods: Sixty patients with symptomatic gall stone diseases undergoing laparoscopic cholecystectomy were randomized into two groups. In study group A (n = 30 patients) 0.5% of 30 mL (150 mg) of ropivacaine, and in control (placebo) group B (n = 30) 30 mL of normal saline was instilled in the gall bladder bed.

Results: Abdominal pain is worse during the first 24 hours after laparoscopic cholecystectomy. After 6 and 12 hours abdominal pain was significantly less in group A compared to group B (P < 0.035). Group A experienced less shoulder tip pain during the first postoperative day, compared to control group.

Conclusions: Intraperitoneal instillation of ropivacaine is more effective than placebo instillation at early postoperative hours in reducing postoperative abdominal pain after laparoscopic cholecystectomy.

Keywords: Laparoscopy; Cholecystectomy; Pneumoperitoneum; Pain; Ropivacaine

1. Background

Gall bladder diseases are known to the mankind for over 2000 years (1). The most common operation of the biliary tract performed these days is cholecystectomy, which is the second most common operation (2). The gold standard treatment for symptomatic cholelithiasis remains Langenbuch's open cholecystectomy for over 100 years. In September 1992 a National Institute of Health consensus conference held in Bethesda concluded that laparoscopic cholecystectomy was treatment of choice for cholelithiasis (3).

Laparoscopic cholecystectomy was defined as any case in which entire cholecystectomy procedure was intended to be performed through laparoscope (4). Advantages of laparoscopic cholecystectomy over open cholecystectomy include reduced pain, shorter hospital stay and recovery period, which affects the patient's earlier return to normal life and working activities (5, 6). In many centers patients are discharged on the first postoperative day. However, as experience expands further, few centers have recently shown that the operation

is safe and feasible even as an outpatient procedure in properly selected patients (7).

Postoperative pain is unpredictable, which explains the need for systematic prevention of pain before the patient wakes up from anesthesia (8). Pain following Laparoscopic Cholecystectomy is multifactorial and is differentiated into three components: visceral, abdominal wall and referred pain to shoulder (9). Pain is worst in the first 24 hours; with visceral pain being worse than abdominal wall pain. Causes of pain may include distension induced neuro-praxia of the phrenic nerves, acid in the peritoneal milieu during operation, residual intra-abdominal gas after laparoscopy, humidity of the insufflated gas, volume of the insufflated gas, wound size; trauma to the parietal peritoneum, presence of drains, anesthetic drugs and their postoperative effect. Carbon dioxide insufflation constitutes the most common means of achieving pneumo-peritoneum. Peritoneal irritation by carbonic acid, which is formed by reaction between CO₂ and water and the creation of space between liver and diaphragm

by residual pneumo-peritoneum has been implicated for visceral and shoulder tip pain (10). Different modalities have been proposed to relieve postoperative pain after laparoscopy like Non steroidal anti inflammatory drugs /opioids, intraperitoneal local anesthetics, port site infiltration of local anesthetics, intraperitoneal saline, removal of insufflation gas or gas drains, low pressure abdominal insufflations, acetazolamide administration, use of N₂O instead of CO₂ (11).

Local anesthetics are widely used, have a good safety profile and are available in long acting preparations. They provide the benefit of anesthesia without the systemic side effects. Local anesthetics block the generation and propagation of action potentials in nerve and other excitable tissues in a reversible manner, probably at the level of the passive sodium channels (12). Recently, the intraoperative use of local anesthesia during laparoscopy has generated interest. Ropivacaine is a long acting amide-type local anesthetic, released for clinical uses in 1996. When ropivacaine is given intraperitoneally it starts acting within 10 to 20 minutes, and duration of action lasts for four to six hours.

2. Objectives

The present study was conducted to evaluate the efficacy of intraperitoneal instillation of ropivacaine for postoperative pain relief during laparoscopic cholecystectomy.

3. Patients and Methods

The study is a prospective, randomized, controlled clinical trial. Participants were recruited to the tertiary hospital from March 1st, 2012, through November 30th, 2012. Approval of the study was obtained from the local ethics committee, and informed consent was obtained from all patients. Sixty patients with symptomatic gall stone disease undergoing laparoscopic cholecystectomy were randomized into two groups by distributing two different color cards among the patients equally (red-study: group A, yellow-control: group B). Cards were picked up blindly by the resident doctor and distributed to the patients. The inclusion criteria were as follows: age between 16 to 70 years, symptomatic cholelithiasis, no clinical, biochemical or ultrasound evidence of CBD stones. The exclusion criteria were as follows: hypersensitivity to ropivacaine, age below 16 years, acute cholecystitis, pregnancy, history of peritonitis. Laparoscopic cholecystectomy was performed while the patient was positioned in a slight reverse trendelenburg with a 4 trocar technique, according to the "American" variable in all the patients. The pressure of CO₂ was kept stable at 10 mmHg during the procedure.

A silicone catheter (epidural catheter) was inserted through the lateral trocar under the direct vision of laparoscope, so that the tip of the catheter is placed in the bed of the gall bladder. Then in group A 0.5% of 30 mL ropivacaine was instilled, and in group B 30 mL of normal saline

was instilled in the gall bladder bed. No drains were used. Antibiotic prophylaxis was given with three doses of a second generation cephalosporin. There was no case of gall bladder perforation or bile stone spillage.

An independent nurse recorded the postoperative abdominal and shoulder tip pain at the 6th, 12th, 24th, and 48th hour after the operation according to patient's perception. The randomization was blind to both of them. Pain assessment was based on a 0 to 10 visual analogue scale (VAS, 0: no pain, 10: the worst imaginable pain). Preoperatively, the nurse introduced patients to the concept of a VAS scale. If the VAS score was above 3, an intramuscular (IM) injection of diclofenac 75 mg was applied. If pain was persistent, the diclofenac IM injection was repeated. Postoperative nausea was noted. The nausea was assessed by the patient's complaint and the need for the use of an antiemetic drug. Parametric data were compared between groups by analysis of variances (ANOVA) and post hoc testing. Nonparametric data were analyzed with Mann-Whitney test and chi-square tests between groups. Statistical significance was assumed if $P < 0.05$.

4. Results

There was no difference found in the age, sex and duration of the surgery between the two groups. Laparoscopic cholecystectomy was performed in the study group A in three men and 27 women with mean age of 41 years (range of 26-70), and in the control group B group in three men and 27 women with mean age of 43 years (range of 21-60) (Table 1). The laparoscopic procedure was completed successfully in all cases without any intraoperative complications or need of conversion to an open operation. The mean duration of the operation was 49 minutes (range 35 to 65) in the study group A, and 40 minutes (range 36 to 58) in the control group B. In our study, average hospital stay was 1.56 days in both the groups. The VAS score for abdominal pain in group A was significantly less compared to group B after 6 hours ($P < 0.040$), 12 hours ($P < 0.002$) and 24 hours ($P < 0.001$). At 48th hour the VAS score was not significant ($P > 0.05$) (Table 2) (Figure 1).

The VAS score for shoulder tip pain for group A compared to group B was significant at 6th hour ($P < 0.012$), whereas it was insignificant at 12th hours, 24th hours, and 48th hours ($P > 0.05$) (Figure 2). At 6th hour 6.66% patients in group A and 63.33% patients in group B were given analgesic injections. P value (< 0.0001) calculated was significant between group A and group B. After 12 hours 10% patients in group A and 33.33% patients in group B were given analgesic injections. P value (0.0575) calculated was insignificant between group A and group B. After 24 hours 6.66% of patients were given analgesic injections in both groups. After 48 hours none of the patients from neither groups were given analgesic injections (Table 3).

Table 1. Patient Demographic, Surgical Data, Hospital Stay^a

	Group A	Group B
Age, y	41 ± 11	43 ± 10
Gender, male/ female	3/27	3/27
Duration of surgery, min	49 ± 11	40 ± 12
Hospital stay, d	1.56 ± 0.67	1.56 ± 0.62

^a Data are presented as mean ± SD.

Table 2. Comparison Between VAS Score for Abdominal Pain and Shoulder Tip Pain Between Two Groups

Time, h	Group A vs. B (Pain Abdomen)	Group A vs. B (Shoulder Tip pain)
6	0.040	0.012
12	0.002	0.476
24	0.001	0.576
48	0.206	0.374

Table 3. Frequency of Analgesic^a

	Patients Requiring Analgesics	
	Group A	Group B
Total number	30 (100)	30 (100)
Injection time, h		
6	2 (6.66)	19 (63.33)
12	3 (10.0)	10 (33.33)
24	2 (6.66)	2 (6.66)
48	0 (0)	0 (0)

^a Data are presented as No. (%).

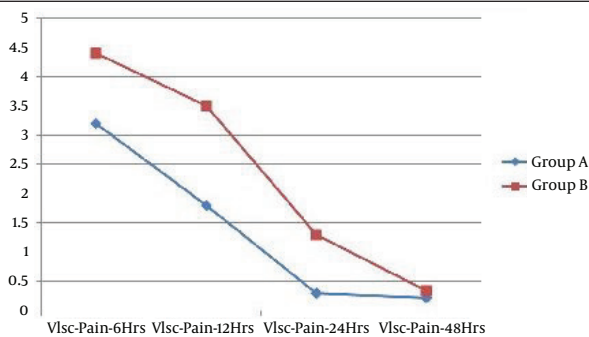


Figure 1. Comparison of VAS Score for Visceral Pain Between Two Groups

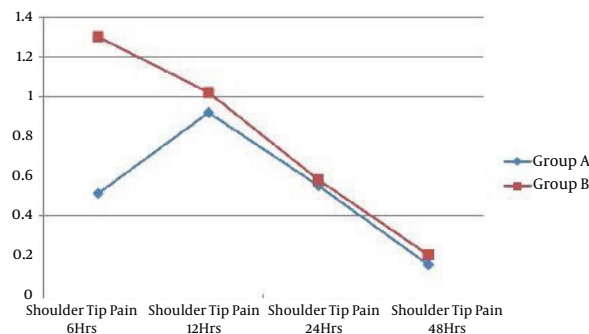


Figure 2. Comparison of VAS Score for Shoulder Tip Pain Between Two Groups

5. Discussion

Pain after laparoscopic surgery may be transient or may persist for about three days (13). It may cause more discomfort to the patient than the pain at the incision sites. In our study, intraperitoneal instillation of ropivacaine reduced the incidence and intensity of upper abdominal pain and shoulder pain after laparoscopic surgery. Our study demonstrates that the intra peritoneal instillation of ropivacaine reduces abdominal pain and shoulder tip pain significantly after LC. The VAS score for pain abdomen in group A (ropivacaine group) was significantly less, compared to group B (placebo group) at 6th ($P < 0.039$), 12th ($P < 0.001$) and 24th hours ($P < 0.001$) (Table 2). The VAS score for shoulder tip pain between study group A and control group B was significant at 6th hour ($P < 0.018$) (Table 2). The total analgesic injection demand was less in group A compared to control group B. After 6 hours analgesic requirement for group A patients compared to group B patients ($P < 0.0001$) was significant, whereas at 12th, 24th, and 48th hours difference of analgesic requirement between group A and group B was insignificant (Table 3). The frequency of nausea in the early postoperative period in the study group A was less, compared to control group, but not significant.

Our results are in concordance with Labaille et al. (14) who also found significant reduction in the visceral pain in patients receiving ropivacaine in gall bladder bed immediately after trocar placement and at the end of surgery. Ingelmo et al. (15) found that preoperative nebulization of peritoneal cavity with ropivacaine significantly reduces postoperative pain. Our study is also in concordance with various authors; Gupta et al. (16), Trikoupis et al. (17), Kucuk et al. (18), Memedov et al. (19), Pavlidis et al. (20), Park et al. (21), who have found intra peritoneal instillation of local anesthesia decreases the visceral pain after laparoscopic surgery. However study conducted by Bisgaard et al. failed to show any decrease in the visceral pain after intraperitoneal instillation of ropivacaine (22). This could be due to reduced dosage used for intraperitoneal instillation. There are other studies conducted using local anesthetics but they did not find any benefit for intraperitoneal instillation of local anesthesia to decrease pain after laparoscopic cholecystectomy (23, 24). Cha et al. and Callesen et al. found significant reduction of shoulder tip pain in patients receiving intraperitoneal instillation of ropivacaine which is shown by the present study too (25, 26). However, our study do not agree with studies of Pavlidis et al. (20) and Bisgaard et al. (22), which failed to show any decrease in the shoulder tip pain after intraperitoneal instillation of ropivacaine.

Instillation of local anesthesia intra-abdominally has had mixed effect with approximately half of the studies showing that it is beneficial. The reason for variation in their result is not known. However, the difference may be due to enrolling patients with acute cholecystitis in their study. In fact, it is possible in these cases that the presences of acute inflammation may trigger neuronal

sensation itself. Factors which may affect the benefit of intra peritoneal instillation of Local anaesthetic are: the site of instillation (subdiaphragmatic or subhepatic or gall bladder bed), dose and the concentration of the LA used, pneumo-peritoneum (volume pressure and temp of CO₂), volume of residual CO₂ (causing diaphragmatic irritation), spillage of bile and blood (may interfere with absorption), degree of nonvisceral pain (pain from incision site), postoperative analgesic regimen. It has been suggested that postoperative pain is reduced, if suppression of central neuronal sensitization by intra peritoneal LA occur before nociceptive stimuli have triggered the activation of pathway. Intraperitoneal instillation of LA may trigger other mechanisms that can relieve postoperative pain, besides the modulation of central hyper excitability. LA may also have anti-inflammatory effect on peripheral nociceptors which would relieve primary hyperalgesia (27). The plasma concentration of ropivacaine was not measured as we believed our concentration was nontoxic, which is supported by this and previous clinical trial (27).

Hence, our study demonstrates that intraperitoneal instillation of ropivacaine reduces the incidence and intensity of upper abdominal pain and shoulder tip pain after laparoscopic cholecystectomy.

Authors' Contributions

Study, concept and design: Pankaj Dugg, Pankaj Shivhare, Anand Munghate; Acquisition of data: Pankaj Dugg, Pankaj Shivhare; Analysis and interpretation of data: Harnam Singh, Sushil Mittal and Ashwani Kumar; Drafting of the manuscript: Pankaj Dugg and Pankaj Shivhare; Critical revision of the manuscript for important intellectual content: Harnam Singh and Sushil Mittal; Statistical analysis: Pankaj Shivhare, Ashwani Kumar, Anand Munghate; Administrative, technical and material support: Pankaj Dugg, Pankaj Shivhare and Sushil Mittal; Study supervision: Sushil Mittal and Harnam Singh

References

1. Shehadi WH. The biliary system through the ages. *Int Surg*. 1979;**64**(6):63-78.
2. Cuschieri A, Dubois F, Mouiel J, Mouret P, Becker H, Buess G, et al. The European experience with laparoscopic cholecystectomy. *Am J Surg*. 1991;**161**(3):385-7.
3. De U. Evolution of cholecystectomy: A tribute to Carl August Langenbuch. *Ind J Surg*. 2004;**66**(2):97-100.
4. A prospective analysis of 1518 laparoscopic cholecystectomies. The Southern Surgeons Club. *N Engl J Med*. 1991;**324**(16):1073-8.
5. Lahmann B, Adrales GL, Mastrangelo MJ, Jr, Schwartz RW. Laparoscopic cholecystectomy-technical considerations. *Curr Surg*. 2002;**59**(1):55-8.
6. Zucker KA, Bailey RW, Flowers J. Laparoscopic management of acute and chronic cholecystitis. *Surg Clin North Am*. 1992;**72**(5):1045-67.
7. Kum CK, Wong CW, Goh PM, Ti TK. Comparative study of pain level and analgesic requirement after laparoscopic and open cholecystectomy. *Surg Laparosc Endosc*. 1994;**4**(2):139-41.
8. Gupta R, Bogra J, Kothari N, Kohli M. Postoperative analgesia with intraperitoneal fentanyl and bupivacaine: a randomized

- control trial. *Can J Med*. 2010;**1**(1):1-11.
9. Joris J, Thiry E, Paris P, Weerts J, Lamy M. Pain after laparoscopic cholecystectomy: characteristics and effect of intraperitoneal bupivacaine. *Anesth Analg*. 1995;**81**(2):379-84.
10. Alexander JL, Hull MG. Abdominal pain after laparoscopy: the value of a gas drain. *Br J Obstet Gynaecol*. 1987;**94**(3):267-9.
11. Wills VL, Hunt DR. Pain after laparoscopic cholecystectomy. *Br J Surg*. 2000;**87**(3):273-84.
12. de Jong E, Field JA, Spinnler HE, Wijnberg JB, de Bont JA. Significant biogenesis of chlorinated aromatics by fungi in natural environments. *Appl Environ Microbiol*. 1994;**60**(1):264-70.
13. Dixon JB, Reuben Y, Halket C, O'Brien PE. Shoulder pain is a common problem following laparoscopic adjustable gastric band surgery. *Obes Surg*. 2005;**15**(8):1111-7.
14. Labaille T, Mazoit JX, Paqueron X, Franco D, Benhamou D. The clinical efficacy and pharmacokinetics of intraperitoneal ropivacaine for laparoscopic cholecystectomy. *Anesth Analg*. 2002;**94**(1):100-5.
15. Ingelmo PM, Bucciero M, Somaini M, Sahillioglu E, Garbagnati A, Charton A, et al. Intraperitoneal nebulization of ropivacaine for pain control after laparoscopic cholecystectomy: a double-blind, randomized, placebo-controlled trial. *Br J Anaesth*. 2013;**110**(5):800-6.
16. Gupta A, Thorn SE, Axelsson K, Larsson LG, Agren G, Holmstrom B, et al. Postoperative pain relief using intermittent injections of 0.5% ropivacaine through a catheter after laparoscopic cholecystectomy. *Anesth Analg*. 2002;**95**(2):450-6.
17. Trikoupis A, Papavramidis T, Kyurdzhieva E, Kesisoglou I, Vasiliakos D. Intraperitoneal administration of ropivacaine during laparoscopic cholecystectomy: 14AP12-5. *Eur J Anaesthesiol*. 2010;**27**(47):222.
18. Kucuk C, Kadiogullari N, Canoler O, Savli S. A placebo-controlled comparison of bupivacaine and ropivacaine instillation for preventing postoperative pain after laparoscopic cholecystectomy. *Surg Today*. 2007;**37**(5):396-400.
19. Memedov C, Menteş Ö, Şimşek A, Kece C, Yağci G, Harlak A, et al. Comparison of Analgesic Effects of Intraperitoneal Lornoxicam and Ropivacaine Administration in Laparoscopic Cholecystectomy. *Trakya Univ Tip Fak Derg*. 2010;**27**(2):142-9.
20. Pavlidis TE, Atmatzidis KS, Papaziogas BT, Makris JG, Lazaridis CN, Papaziogas TB. The effect of preincisional periportal infiltration with ropivacaine in pain relief after laparoscopic procedures: a prospective, randomized controlled trial. *JSLs*. 2003;**7**(4):305-10.
21. Park YH, Kang H, Woo YC, Park SG, Baek CW, Jung YH, et al. The effect of intraperitoneal ropivacaine on pain after laparoscopic colectomy: a prospective randomized controlled trial. *J Surg Res*. 2011;**171**(1):94-100.
22. Bisgaard T, Klarskov B, Kristiansen VB, Callesen T, Schulze S, Kehlet H, et al. Multi-regional local anesthetic infiltration during laparoscopic cholecystectomy in patients receiving prophylactic multi-modal analgesia: a randomized, double-blinded, placebo-controlled study. *Anesth Analg*. 1999;**89**(4):1017-24.
23. Rademaker BM, Kalkman CJ, Odoom JA, de Wit L, Ringers J. Intraperitoneal local anaesthetics after laparoscopic cholecystectomy: effects on postoperative pain, metabolic responses and lung function. *Br J Anaesth*. 1994;**72**(3):263-6.
24. Scheinin B, Kellokumpu I, Lindgren L, Haglund C, Rosenberg PH. Effect of intraperitoneal bupivacaine on pain after laparoscopic cholecystectomy. *Acta Anaesthesiol Scand*. 1995;**39**(2):195-8.
25. Cha SM, Kang H, Baek CW, Jung YH, Koo GH, Kim BG, et al. Peritrocal and intraperitoneal ropivacaine for laparoscopic cholecystectomy: a prospective, randomized, double-blind controlled trial. *J Surg Res*. 2012;**175**(2):251-8.
26. Callesen T, Hjort D, Mogensen T, Schouenborg L, Nielsen D, Reventlid H, et al. Combined field block and i.p. instillation of ropivacaine for pain management after laparoscopic sterilization. *Br J Anaesth*. 1999;**82**(4):586-90.
27. Tsai HW, Chen YJ, Ho CM, Hseu SS, Chao KC, Tsai SK, et al. Maneuvers to decrease laparoscopy-induced shoulder and upper abdominal pain: a randomized controlled study. *Arch Surg*. 2011;**146**(12):1360-6.