

Laparoscopic Enucleation and Omentopexy of a Primary Hydatid Spleen: A Case Report and Literature Review

Faroze Ahmad Khan^{1,*}; Sadaf Ali¹; Mohammad Younis¹; Khurshied Ahmad Bhat¹; Mehmooda Akhtar²

¹Department of Surgical Gastroenterology, Sheri Kashmir Institute of Medical Sciences, Srinagar, India

²Department of Surgical Anaesthesiology, Sheri Kashmir Institute of Medical Sciences, Srinagar, India

*Corresponding author: Faroze Ahmad Khan, Department of Surgical Gastroenterology, Sheri Kashmir Institute of Medical Sciences, Srinagar, India. Tel: +91-9906611775, E-mail: drkhan9678@gmail.com

Received: January 19, 2014; Revised: June 11, 2014; Accepted: July 1, 2014

Introduction: Cystic lesions of spleen are rare. Most of these cysts are parasitic and are caused by Echinococcal infection. Various treatment options for splenic hydatid cyst have evolved over the years.

Case Presentation: We report a case of splenic hydatid cyst in a 55-year-old male, managed laparoscopically with enucleation and omentopexy.

Conclusions: In conclusion, we recommend that laparoscopic spleen preserving procedures should be preferred for hydatid spleen when conditions are favorable and enough precautions are taken to prevent spillage. We suggest the use of aspirator for giving the scolical agent and favor the albendazole as an adjuvant therapy to prevent its recurrence.

Keywords: Echinococcal; Hydatid Spleen; Enucleation; Omentopexy

1. Introduction

Hydatid disease (echinococcosis) has a worldwide distribution. Liver (75%) followed by the lungs (15%) are the most common sites of involvement in adults (1, 2). Splenic hydatidosis, although rare, is the third most common type of hydatidosis (1, 3). Open splenectomy is considered the standard treatment (4) but in laparoscopic era, laparoscopic management seems to be better and superior. Our patient had a desire of minimally invasive procedure, so we chose laparoscopic management with organ preservation.

2. Case Presentation

A 55-year-old male presented with pain and heaviness in his left upper quadrant from two months before. He had no other significant positive history of diseases. On examination his spleen was enlarged, just two fingers below the costal margin. Rest of the physical examination was normal. A trans abdominal ultrasonography revealed a 9.3 cm × 9.9 cm well circumscribed cystic lesion at lower pole of spleen with hyperechoic wavy contents within it. While his contrast enhanced computed tomography (CECT) showed a 10 × 10 × 9 cm³ well defined cystic lesion involving lower pole of spleen with curvilinear calcification and evidence of internal calcified contents (membranes) (Figure 1). Hydatid serology of our patient was positive. In view of radiological features, serology

and endemic nature of disease, hydatid cyst of spleen was considered as first diagnosis. To the desire of the patient and favorable location of the cyst, we went for the laparoscopic intervention.

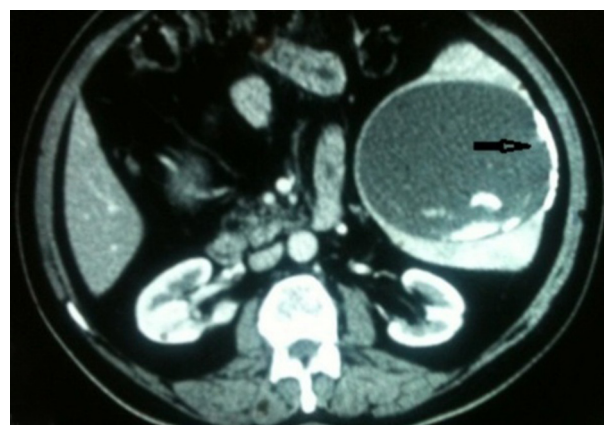


Figure 1. Photograph of CECT Film Showing Cyst With Curvilinear Calcification

2.1. Our Operative Technique

Patient was operated in reverse trendelenburg with left up position using four ports. Three 10mm ports were

inserted; the first one was inserted in umbilical area for telescope, the second in anterior axillary line two fingers below costal margin and the third one in epigastric region just lateral to midline. One 5 mm port in mid clavicular line two fingers above the level of umbilicus. Apart from the umbilical port, the place of other ports was decided after determining the location of the cyst. Greater omentum was found to be adherent to the lower pole of the spleen. After releasing the omental adhesions the cyst wall became apparent. Aspirator needle was inserted and clear fluid was aspirated out (Figure 2). The color and nature of fluid almost confirmed the diagnosis. After decompressing the cyst (without withdrawing the aspirator) the cavity was filled with 10% betadine solution using 50 mL syringe. The amount of povidone-iodine was equivalent to the amount of fluid aspirated out. After waiting for 15 minutes povidone-iodine solution was suctioned out through the same aspirator. Cavity opened membranes were removed into an endobag with a hook. The endobag was filled with membranes delivered out intact with the 10 mm axillary port which was then reinserted. A flap of the omentum was fashioned out and inserted into the cavity. The omentum was fixed using a 2/0 catgut suture. Hemostasis was confirmed and tube drain was inserted through a 10 mm axillary port. Drain was kept near the inferior pole of the spleen. The 10 mm ports was closed with vicryl suture and skin clips were applied. Patient had an uneventful recovery. On the first and second postoperative day, drain output was about 50 mL fluid which was sero-sanguinous. There was minimal serous fluid on third postoperative day. Drain was removed on the 3rd postoperative day and the patient was discharged on the 4th postoperative day. Patient is now in his eight months' follow-up.

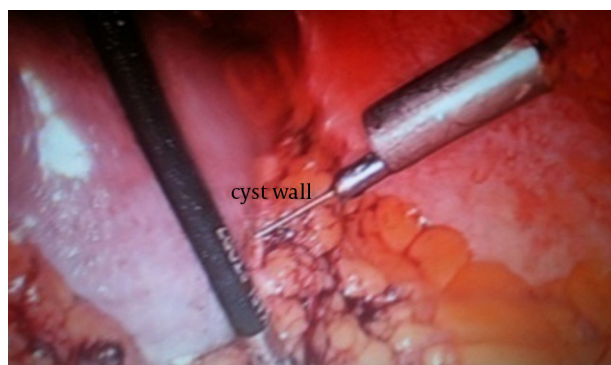


Figure 2. Operative Picture Showing Cyst Wall and Aspirator Needle Being Inserted Into the Cyst Cavity

3. Discussion

Parasitic cysts of spleen are known to be at least twice as common as nonparasitic variety (5) and in endemic areas 50%-80% of splenic cysts are *echinococcal* (6). Hydatid disease of spleen was first described by Berthelot (1791

(7). The most probable routes of primary hydatid cyst of spleen include arterial route. After escaping from liver and lung circulation, the parasite lodges in spleen. Another route is the venous route; the parasite may bypass liver and lung through portal circulation (8). Systemic dissemination or intra peritoneal spread following ruptured hepatic hydatid cyst may usually lead to secondary hydatid spleen (1, 9). The diagnosis mainly depends on imaging modalities, mostly abdominal ultrasonography and computed tomography. The combination of serological tests and imaging characteristics indicate the correct diagnosis in most cases (10, 11).

The definitive treatment guidelines cannot be precisely laid down, as it is a rare disease. The management of splenic cysts has continued to evolve over the years. Open splenectomy has been considered to be the gold standard treatment for the hydatid spleen, even in recent years (4). In the laparoscopic era of the growing experience and new developments of the technical instruments, laparoscopic management has evolved to be more feasible and superior. The possibility of anaphylactic reaction and recurrence due to spillage of fluid into the peritoneal cavity is the main hurdle which has made surgeons reluctant for laparoscopic intervention (12). Those concerns have not been proved in reported laparoscopic series (13). Our technique of giving scolical agent through the aspirator, without withdrawing it minimizes the chances of spillage. A retrospective study done by Polat et al. (14) compared open and laparoscopic hydatid cystectomy. There was no recurrence of the cyst in any patient at least 24 months after the operation. But the morbidity rates of laparoscopic and open approaches were 14.2% and 33.3% respectively. Laparoscopy is beneficial to the patient in terms of early recovery, minimal postoperative pain and better cosmetic appearance (15). Organ sparing procedures should always be performed to avoid OPSI, and great mortality rate of over 50% (16). Atmatzidis et al. compared splenectomy and spleen preserving surgery. The study showed no significant increase in recurrence and postoperative complication rate between the two surgical approaches (17). Most of the other studies that also show recurrence rate after total splenectomy, do not differ significantly from spleen preserving surgery and complication rates are also comparable (17, 18).

Medical treatment with albendazole as an adjuvant therapy should be used to minimize recurrence in case of spillage or occult cysts (19-21). Administering albendazole before surgery may facilitate complete removal of the germinal layer, as also shown by a study (22). It stabilizes cysts, decreases tension inside the cyst, and decreases anaphylaxis and recurrence (23). In our patient we started albendazole one week prior to surgery and continued it for three months with a gap of one week in each month. We have experienced a very low recurrence rate by using combined medical and surgical modalities (24).

In conclusion, we recommend that laparoscopic spleen preserving procedures should be preferred for hydatid spleen when conditions are favorable and enough precautions are taken to prevent spillage. We suggest the use of aspirator for giving the scolicalid agent and favor the albendazole as an adjuvant therapy to prevent its recurrence.

Acknowledgments

We thank our theater team including anesthesiologists and technical staff. We are highly thankful to head of the department of surgical gastroenterology for his kind encouragement and support.

Authors' Contributions

Faroze Ahmad Khan gave the concept and wrote the manuscript. Mohammad Younis, Khurshied Ahmad and Mehmooda Akhtar contributed in preparing the manuscript. Sadaf Ali did the critical revision of the manuscript for important intellectual content.

References

- Safioleas M, Misiakos E, Manti C. Surgical treatment for splenic hydatidosis. *World J Surg.* 1997;**21**(4):374-7.
- Mazumdar A, Singh G, Gupta NM. Primary splenic hydatid in adults. *Trop Gastroenterol.* 2000;**21**(2):78-9.
- Safioleas M, Misiakos EP, Kakisis J, Manti C, Papachristodoulou A, Lambrou P, et al. Surgical treatment of human echinococcosis. *Int Surg.* 2000;**85**(4):358-65.
- Dar MA, Shah OJ, Wani NA, Khan FA, Shah P. Surgical management of splenic hydatidosis. *Surg Today.* 2002;**32**(3):224-9.
- Franquet T, Montes M, Lecumberri FJ, Esparza J, Bescos JM. Hydatid disease of the spleen: imaging findings in nine patients. *AJR Am J Roentgenol.* 1990;**154**(3):525-8.
- Gharaibeh KI. Laparoscopic excision of splenic hydatid cyst. *Postgrad Med J.* 2001;**77**(905):195-6.
- Muro J, Ortiz-Vazquez J, Mino G, Sanmartin P. [Angiographic localization of hydatid cyst of the spleen]. *Rev Clin Esp.* 1969;**115**(5):433-8.
- Fernandez-Ruiz M, Guerra-Vales JM, Enguita-Valls AB, Vila-Santos J, Garcia-Borda FJ, Morales-Gutierrez C. Splenic hydatid cyst, a rare location of extrahepatic echinococcosis: Report of six cases. *Eur J Intern Med.* 2008;**19**(7):e51-3.
- Prousalidis J, Tzardinoglou K, Sgouradis L, Katsolis C, Aletras H. Uncommon sites of hydatid disease. *World J Surg.* 1998;**22**(1):17-22.
- Tarcoveanu E, Dimofte G, Bradea C, Crumpei F, Anton R, Moldovanu R. Multiple peritoneal hydatid disease after rupture of a multivesicular hepatic hydatid cyst. Case report. *J Gastrointest Liver Dis.* 2006;**15**(3):301-5.
- Husen YA, Nadeem N, Aslam F, Bhaila I. Primary splenic hydatid cyst: a case report with characteristic imaging appearance. *J Pak Med Assoc.* 2005;**55**(5):219-21.
- Katkhouda N, Hurwitz M, Gugenheim J, Mavor E, Mason RJ, Waldrep DJ, et al. Laparoscopic management of benign solid and cystic lesions of the liver. *Ann Surg.* 1999;**229**(4):460-6.
- Brunt LM, Langer JC, Quasebarth MA, Whitman ED. Comparative analysis of laparoscopic versus open splenectomy. *Am J Surg.* 1996;**172**(5):596-9.
- Polat FR. Hydatid cyst: open or laparoscopic approach? A retrospective analysis. *Surg Laparosc Endosc Percutan Tech.* 2012;**22**(3):264-6.
- Cala Z, Cvitanovic B, Perko Z, Velnic D, Rasic Z. Laparoscopic treatment of nonparasitic cysts of spleen and liver. *J Laparoendosc Surg.* 1996;**6**(6):387-91.
- Holdsworth RJ, Irving AD, Cuschieri A. Postsplenectomy sepsis and its mortality rate: actual versus perceived risks. *Br J Surg.* 1991;**78**(9):1031-8.
- Atmatzidis K, Papaziogas B, Mirelis C, Pavlidis T, Papaziogas T. Splenectomy versus spleen-preserving surgery for splenic echinococcosis. *Dig Surg.* 2003;**20**(6):527-31.
- Rahmani SH, Mohammadi Tofigh A. Spleen preserving surgery versus splenectomy for splenic hydatid cyst: ten years experience. *Shiraz e Med J.* 2008;**9**(2):82-7.
- Karavias DD, Vagianos CE, Bouboulis N, Rathosis S, Androulakis J. Improved techniques in the surgical treatment of hepatic hydatidosis. *Surg Gynecol Obstet.* 1992;**174**(3):176-80.
- Teggi A, Lastilla MG, De Rosa F. Therapy of human hydatid disease with mebendazole and albendazole. *Antimicrob Agents Chemother.* 1993;**37**(8):1679-84.
- Stamatakis J. Hepatic hydatid disease. In: Johnson CD, Taylor I editors. *Recent Advances In Surgery*. London: Church-ill Livingstone; 1994. pp. 35-48.
- Gokhan A., Oguzhan K, Merih A. Diagnostic problems with parasitic and non-parasitic splenic cysts. *Hepatogastroenterology.* 2001;**49**:235-43.
- Rasheed K, Zargar SA, Telwani AA. Hydatid cyst of spleen: a diagnostic challenge. *N Am J Med Sci.* 2013;**5**(1):10-20.
- Sadaf A, Bhat Muneer A, Reyaz Latt O, Khairat M, Omar JS, Showkat AZ. An experience of 58 cases of Hydatid Liver treated surgically in a tertiary care hospital in an endemic area of Kashmir Valley in India. *Pak J Surg.* 2011;**27**(4):250-5.