


## Intestinal Herniation after Laparoscopic Roux-en-Y Gastric Bypass, Letter to Editor

Shahab Shahabi<sup>1</sup>, Negin Salemi<sup>2\*</sup>, Behrouz Keleidari<sup>3</sup> 

Received: Feb 02, 2021/ Published Online: Feb 17, 2021

### To the Editor

Laparoscopic Roux en Y gastric bypass (LRYGB) as a gold standard bariatric surgery has proven to be effective procedure for weight loss and a high resolution of obesity related diseases. IH is a well-known late complication of a LRYGB

The incidence of IH after LRYGBP has been reported to be between 0.5 and 11% [1]. Clinical symptoms related to an IH can vary from vague nonspecific symptoms, like intermittent or postprandial pain to persistent abdominal pain and an acute abdomen [2]. Because of the nonspecific clinical presentation and the absence of reliable diagnostic imaging, it can cause a high morbidity and even mortality. This is a significant clinical problem since IH is the most common cause of small bowel obstruction (SBO) after LRYGB [3, 4]. The possible mesenteric spaces after LRYGB arise at typical locations. In antecolic antegastric LRYGB, there are two primary locations of IH: an open space between the alimentary (Roux) limb and the transverse colon (called Petersen's space) or a mesojejunal space at the jejunojejunostomy. Here, we present IH 4 years after LRYGB even though primary repair of mesojejunal space. The presented cases emphasize the diagnostic difficulties and the need for early surgical exploration.

our manuscript included one case of Intestinal Herniation after Laparoscopic Roux-en-Y Gastric Bypass:

A 31 Y/O Iranian morbid obese man (BMI=46.29) who had underwent LRYGB 4 years ago, presented in the emergency room with a history of upper abdominal cramps, nausea and vomiting during the last 3 days. He reported abdominal cramp which was a colic pain at the epigastric and right upper part during 4 months, gotten worse while eating and sitting. The postoperative course was without problems and the patient had lost 70 kg (BMI 24.69 kg/m<sup>2</sup>). He was operated for laparoscopic cholecystectomy a year ago.

Physical examination showed a mild abdominal tenderness at the right upper quadrant and epigastric part. On gastroesophageal endoscopy, the gastric remnant was connected to two loops of the jejunum and a biopsy of jejunum was taken which was within normal limits. His chest-x-ray and standing abdominal graphy was normal. On ultrasound there was no free fluid in the abdominal cavity, the liver had a normal shape and size and parenchymal echo. The common bile duct and portal diameter were normal. His hematological laboratory data were normal. Also, an abdominal CT was inconclusive. Finally, for his abdominal pain, he went on a diagnostic laparoscopy. We found the intestine was herniated into mesojejunal space so for a more exact survey abdomen was opened with a small incision above the umbilicus and the internal hernia was confirmed (figure1).The herniated intestine was reset and the defect repaired. As you see in figure 1, our roux limb was placed antecolic, the whole intestine was herniated into mesojejunal which was repaired with non-absorbable running suture before.

The herniated intestine was reset and the defect repaired with prolene 2/0 running suture (Figure2).

The post-operative was uneventful and patient discharged postoperative day 2. In his follow up after 3 month all sign and symptoms were disappeared.

Although Internal hernia (IH) is more common after LRYGB than after open surgery. One of the most common and also the most devastating complications that can arise after LRYGB is an IH [5]. It is a particularly sinister complication with a various and nonspecific presentation [6]. Nonspecific symptoms, making the diagnosis challenging. Most patients report a combination of postprandial abdominal pain, nausea, and emesis [7].

Although mesojejunal space was repaired in primary surgery with non-absorbable suture in our case, a large part of the small intestine herniated through mesojejunal defect. This had resulted in partial bowel obstruction. There is increasing evidence, that primary closure can reduce the incidence of IH [8,9]. De la Cruz-Muñoz and colleagues reviewed 2079 patients after LRYGB surgery and compared IH incidences before and after they started to routinely close mesenteric defects at the initial surgery. They found a significant reduction of IH incidence. Closing mesenteric defects may also bear a risk for complications [10]. In a another study by Blockhuys et al. in large number of patients they strongly recommended of clo-

1. Fellowship in advanced MIS and bariatric surgery, Isfahan University of medical sciences, Isfahan, Iran

2. Medical student, Isfahan University of medical sciences, Isfahan, Iran

3. Associate professor, Fellowship in advanced MIS and bariatric surgery, Isfahan University of medical sciences, Isfahan, Iran

\* Negin Salemi, [n.salemi96@gmail.com](mailto:n.salemi96@gmail.com)

sure of both mesenteric defect and Petersen's space, with notice a tendency to lower incidence of internal hernias (incidence of 3.34% comparing 1.15% in the closure group of both defects)[11].

In a study by Goudsmedt et al. the found swirl was in CT scan the best predictor of internal hernia with sensitivity of 68-89%, since the presented sensitivities are variable and do not reach 100 % [12] IH might be missed, implicating that a high index of suspicion with a low

threshold for explorative laparoscopy/-tomy remains the cornerstone of appropriate treatment.

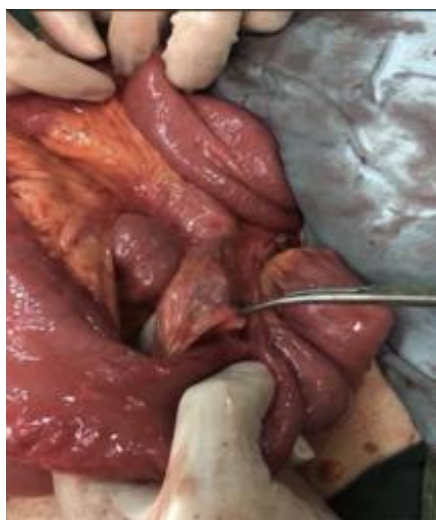

Figure 1. Internal hernia into mesojejunal space which was repaired with non-absorbable running suture before

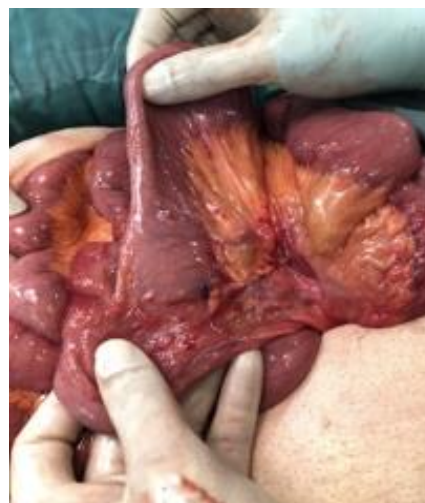

Figure 2. Reduction of internal hernia from mesojejunal space and repair of defect with prolene 2/0 running suture

**Conflicts of Interest:** The authors declared no conflict of interest

**Funding:** None

**This work has been published under CC BY-NC-SA 4.0 license.**

Copyright© [Iran University of Medical Sciences](http://www.iums.ac.ir)

**Cite this article as:** Shahabi SH, Salemi N, Keleidari B. Intestinal Herniation after Laparoscopic Roux-en-Y Gastric Bypass, Letter to Editor. *Ann Bariatr Surg.* 2020(May);9(1).8.

## References

1. Iannelli A, Buratti MS, Novellas S, et al. Internal hernia as a complication of laparoscopic roux-en-Y gastric bypass. *Obes Surg.* 2007;17(10):1283-6. 2.
2. Marmuse JP, Parenti LR. Gastric bypass. Principles, complications, and results. *J Visc Surg.* 2010;147(5 Suppl):e31-7.
3. Robert M, Espalieu P, Pelascini E, et al. Efficacy and safety of one anastomosis gastric bypass versus Roux-en-Y gastric bypass for obesity (YOMEGA): a multicentre, randomised, open-label, non-inferiority trial. *Lancet.* 2019;393(10178):1299-309.
4. Rosenthal R, Szomstein S, Kennedy C, Zundel N. Direct visual insertion of primary trocar and avoidance of fascial closure with laparoscopic Roux-en-Y gastric bypass. *Surgical endoscopy.* 2007;21(1):124-8.
5. Filip JE, Mattar SG, Bowers SP, Smith CD. Internal hernia formation after laparoscopic Roux-en-Y gastric bypass for morbid obesity. *The American surgeon.* 2002;68(7):640.
6. Garza Jr E, Kuhn J, Arnold D, Nicholson W, Reddy S, McCarty T. Internal hernias after laparoscopic Roux-en-Y gastric bypass. *The American journal of surgery.* 2004;188(6):796-800.
7. Kassir R, Debs T, Blanc P, et al. Complications of bariatric surgery: presentation and emergency management. *Int J Surg.* 2016;27:77-81.
8. Frøkjær JB, Jensen WN, Holt G, Omar HK, Olesen SS. The diagnostic performance and interrater agreement of seven CT findings in the diagnosis of internal hernia after gastric bypass operation. *Abdominal Radiology.* 2018;43(12):3220-6.
9. Gumbs AA, Duffy AJ, Chandwani R, et al. Jejunojunctional anastomotic obstruction following laparoscopic Roux-en-Y gastric bypass due to non-absorbable suture: a report of seven cases. *Obes Surg* 2006;16:12-15.
10. De la Cruz-Muñoz N, Cabrera JC, Cuesta M, et al. Closure of mesenteric defect can lead to decrease in internal hernias after Roux-en-Y gastric bypass. *Surg Obes Relat Dis* 2011;7:176-80.
11. Blockhuys M, Gypen B, Heyman S, Valk J, van Sprundel F, Hendrickx L. Internal Hernia After Laparoscopic Gastric Bypass: Effect of Closure of the Petersen Defect - Single-Center Study. *Obes Surg.* 2019 Jan;29(1):70-75. doi: 10.1007/s11695-018-3472-9. PMID: 30167987
12. Goudsmedt, F., Deylgat, B., Coenegrachts, K. et al. Internal Hernia After Laparoscopic Roux-en-Y Gastric Bypass: a Correlation Between Radiological and Operative Findings. *OBES SURG* 25, 622-627 (2015). <https://doi.org/10.1007/s11695-014-1433-5>