

Intrahepatic Glissonian Approach in Laparoscopic Right Hepatectomy

Jose F Noguera^{1,*}, Gonzalo Martin¹, Jose Munoz², Jose C Vicens², Jose V Roig¹

¹Consortio Hospital General Universitario de Valencia, Valencia, Spain

²Hospital Son Llàtzer, Palma de Mallorca, Palma, Spain

*Corresponding author: Jose F Noguera, Consortio Hospital General Universitario de Valencia, Valencia, Spain. Tel: +34-961972000, Fax: +34-96197292, E-mail: E-mail: drjfnoguera@hotmail.com.

Received: March 29, 2013; Accepted: August 8, 2013

Introduction: Laparoscopic surgery is still uncommon for major liver resections. The intrahepatic Glissonian approach is a fast and secure way to control the hepatic pedicle.

Case Presentation: A patient diagnosed with stenosing sigmoid adenocarcinoma (T3 N1 M+) (N+, positive lymph nodes, M+ positive metastatic disease) with synchronous liver metastases in segments 7 (8 mm), 6-7 (6 cm) and 3 (12 mm) was recruited to the study. Laparoscopic sigmoidectomy was performed; after a partial response to neoadjuvant chemotherapy, a right hepatectomy was performed. Surgery was performed in the modified Lloyd Davies position by placing 5 trocars. The hepatic pedicle was controlled by the intrahepatic individualized section of the right Glissonian anterior and posterior pedicles. The operation lasted for 5 hours. No intraoperative or postoperative complications occurred. The patient was discharged from the hospital on the fourth postoperative day. The final histopathology showed metastatic colorectal adenocarcinoma in segments 6-7 with right hepatic vein involvement and tumor-free margins.

Conclusions: Although this approach is beneficial, it should be performed by experienced surgeons. We believe that this technique is faster, safer, easier and more reproducible than hilar dissection. This approach can help develop the use of minimally invasive surgery for major liver resections.

Keywords: Hepatectomy; Laparoscopy; Neoplasm Metastasis

1. Introduction

Laparoscopic surgery is uncommon for major liver resections. The intrahepatic Glissonian approach is a fast and secure way to control the hepatic pedicle. The minimally invasive right hepatectomy technique with the intrahepatic Glissonian approach is described in a case of liver metastasis from colorectal cancer.

2. Case Presentation

In a 73-year-old woman, with a history of diabetes and hypertension, a tumor was diagnosed by CT scan and colonoscopy. Stenosing sigmoid adenocarcinoma (T3 N1 M1) with synchronous liver metastases was found in segments 7 (8 mm), 6-7 (6 cm) and 3 (12 mm). Laparoscopic sigmoidectomy was performed, resulting in sigmoid adenocarcinoma pT3 N1 M1. After 6 months Folfiri neoadjuvant treatment, a partial response was observed with persistent 4 cm metastases located in segments 6-7, and right hepatic vein involvement. The Oncological Committee decided in favour of a right hepatectomy and the informed consent was obtained for the surgery and new approach.

The patient was placed in a modified Lloyd-Davies position, in which the surgeon stands between the patient's legs, and the first and second assistants stand at the left and right corner, respectively. We used 5 trocars (12 mm x 2, 5 mm x 2, 10 mm x 1) and a 30° optical. Intraoperative ultrasound (BK Medical, Copenhagen, Denmark) revealed a metastatic subcapsular scar in segment 3 and a 4 cm metastatic lesion in segments 6-7. The duct and cystic artery were sectioned without completing the cholecystectomy. We then placed a Penrose drain around the hepatic hilum to induce ischemia by placing clips on it.

Next, using a gallbladder traction, we performed the intrahepatic right anterior pedicle clamping (Figure 1), objectifying the hepatic ischemic area that delimited the transect line. We then controlled the intrahepatic hemorrhage of the right anterior (Figure 2) and posterior Glissonian pedicles with a vascular stapler (Endo GIATM Tri-Staple 45/2.5 mm, Covidien, Mansfield, USA). In the next step, round and falciform ligaments were sectioned to reach the hepatic veins. We proceeded to the right triangular ligament release, dissected the inferior cava vein and ligated the hepatic vessels sections using a Hem-o-Lock® (Teleflex Medical, Durham, USA). Ablation of the meta-

Implication for health policy/practice/research/medical education:

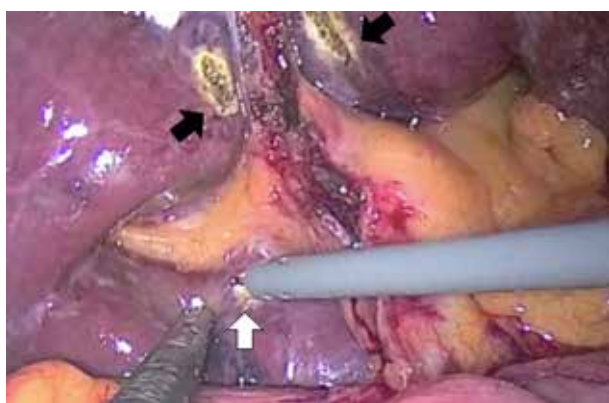
This article gives more evidence to a safe and quick approach to control the liver pedicle in liver laparoscopic surgery.

Copyright © 2014, Minimally Invasive Surgery Research Center and Mediterranean & Middle Eastern Endoscopic Surgery Association. This is an open-access article distributed under the terms of the Creative Commons Attribution License, which permits unrestricted use, distribution, and reproduction in any medium, provided the original work is properly cited.

static scar located in segment 3 was performed using the Tissuelink Endo FB 3.0 (Tissuelink™ Medical, Dover, USA). We, then, began hepatectomy medial to the gallbladder and progressed cranially by a harmonic scalpel (Harmonic Ace, Ethicon Endo-Surgery, Cincinnati, USA) and the Tissuelink Endo FB 3.0 (Tissuelink Medical, Dover, USA).

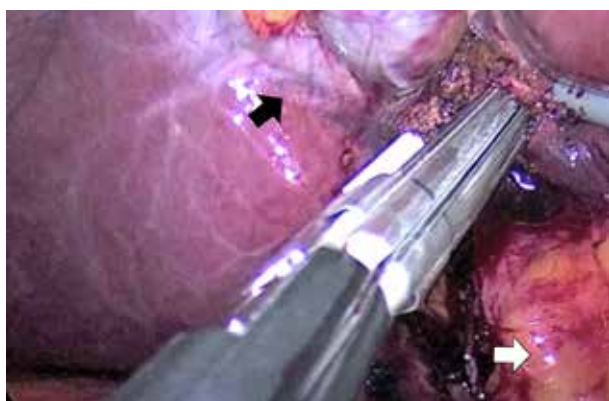
Upon reaching its anatomic location, the right hepatic vein was dissected and divided by vascular stapler (Endo GIATM Tri-Staple 45/2.5 mm, Covidien). Finally, superficial hemostasis was performed, a Jackson-Pratt drain was placed in the subdiaphragmatic space, and the specimen was removed by a plastic bag (Endo Catch™, Covidien, Mansfield, USA) through a 10 cm Pfannestiel incision.

Figure 1. Intraoperative Image



Black and white arrows indicate the location of the right anterior and posterior pedicle clamps, respectively.

Figure 2. Transection of the right anterior pedicle



The figure shows the right anterior Glissonian pedicle section with stapler. The black arrow indicates the gallbladder, and the white arrow indicates the hepatoduodenal ligament.

The operation lasted for 5 hours. No intraoperative or postoperative complications occurred. The patient was discharged from the hospital on the fourth day. The final histology showed metastatic colorectal adenocarcinoma in segments 6-7 with right hepatic vein involvement and

tumor-free margins.

3. Discussion

Since Gangner et al. published the first successful case of laparoscopic hepatectomy in 1992 (1), the use of minimally invasive surgery for minor resections and left hepatectomies has achieved popularity (2). Although totally laparoscopic right hepatectomy is a complex procedure, technological development and better understanding of the anatomy have produced encouraging results from accredited groups (3). These benefits include reduced blood loss, shorter hospital stays and fewer complications in laparoscopic surgery versus open surgery (2). Furthermore, similar results were found regarding medium-term survival in the treatment of liver metastases from colorectal cancer. Driven by the benefits of fully laparoscopic right hepatectomy, data exists regarding benign lesions (4). The main problem for the reproducibility of major laparoscopic hepatectomy is the vascular pedicle control. Thus, the intrahepatic section blockage of the anterior and posterior right Glissonian pedicles (5) seems to be a safer, faster, and less complex approach than hilar dissection (6, 7). Figueras et al. published a prospective randomized study in 2003, comparing both approaches in open surgery and demonstrated that, when done by experienced hands, both techniques are equally effective, with similar results and lower operating time for the blocked intrahepatic pedicle section (8). A contraindication to this approach would be tumors located in the vicinity of the right portal pedicle. Based on scientific evidence, the "Kelly-clysis" technique is ideal for liver transections (9). For all other devices, (i.e. staplers, ultrasonic dissectors, bipolar forceps, etc.) there is no consensus; thus, the best option is to use these devices in combination (9). Although the benefits of this technique should be evaluated by experts, we think that it is faster, safer, more reproducible and simpler than hilar dissection. This approach can aid in developing the use of minimally invasive surgery for major liver resections.

Acknowledgements

None declared.

Authors' Contribution

The authors have contributed to the diagnosis, surgery and follow up of the clinical case, and to the elaboration of the manuscript.

Financial Disclosure

The authors have nothing to disclose in relation to the manuscript.

Funding/Support

The paper has not been supported by any grant or finan-

cial support. There isn't any sponsor for the clinical case.

References

1. Castaing D, Vibert E, Ricca L, Azoulay D, Adam R, Gayet B. Oncologic results of laparoscopic versus open hepatectomy for colorectal liver metastases in two specialized centers. *Ann Surg.* 2009;**250**(5):849-55.
2. Dagher I, Di Giuro G, Dubrez J, Lainas P, Smadja C, Franco D. Laparoscopic versus open right hepatectomy: a comparative study. *Am J Surg.* 2009;**198**(2):173-7.
3. Tzanis D, Shivathirthan N, Laurent A, Abu Hilal M, Soubrane O, Kazaryan AM, et al. European experience of laparoscopic major hepatectomy. *J Hepatobiliary Pancreat Sci.* 2013;**20**(2):120-4.
4. Poves I, Martinez-Serrano Mde L, Burdio F, Coll S, Grande L. [Totally laparoscopic right hepatectomy with hilar dissection]. *Cir Esp.* 2012;**90**(4):261-2.
5. Takasaki K. Glissonean pedicle transection method for hepatic resection: a new concept of liver segmentation. *J Hepatobiliary Pancreat Surg.* 1998;**5**(3):286-91.
6. Habib M, Cresswell AB, Chandrakumaran K, Welsh FK, John TG, Rees M. Extrahepatic versus intrahepatic hilar control for right hepatectomy: an updated experience. *Dig Surg.* 2012;**29**(1):18-22.
7. Yamamoto M, Katagiri S, Ariizumi S, Kotera Y, Takahashi Y. Glissonean pedicle transection method for liver surgery (with video). *J Hepatobiliary Pancreat Sci.* 2012;**19**(1):3-8.
8. Figueras J, Lopez-Ben S, Llado I, Rafecas A, Torras J, Ramos E, et al. Hilar dissection versus the "glissonean" approach and stapling of the pedicle for major hepatectomies: a prospective, randomized trial. *Ann Surg.* 2003;**238**(1):111-9.
9. Scalzone R, Lopez-Ben S, Figueras J. How to transect the liver? A history lasting more than a century. *Dig Surg.* 2012;**29**(1):30-4.