

Laparoscopic Gonadectomy in Patients with Mosaic Turner Syndrome and Complete Androgen Insensitivity Syndrome: A Report of 2 Cases and Review of the Surgical Aspects

Alyssa Sze-Wai Wong^{1,*}, Pong-Mo Yuen²

¹ Department of Obstetrics and Gynaecology, Chinese University of Hong Kong, Hong Kong SAR, China

² Department of Obstetrics and Gynaecology, Hong Kong Sanatorium and Hospital, Hong Kong SAR, China

*Corresponding author: Alyssa Sze-Wai Wong, Department of Obstetrics and Gynaecology, Chinese University of Hong Kong, Hong Kong SAR, China. Tel: +852-26322582, Fax: +852-26360008, E-mail: alyssawong@cuhk.edu.hk

Received: October 08, 2012; Accepted: January 26, 2013

Women with mosaic Turner syndrome (TS) bearing the presence of Y chromosome material or with complete androgen insensitivity syndrome (CAIS) is at risk of gonadal malignancy. Two patients with characteristic features of these uncommon disorders are reported, and the surgical techniques of laparoscopic gonadectomy are reviewed and discussed. The aim of the present study is to report 2 clinical cases and review the surgical aspects of laparoscopic gonadectomy. Both patients had gonadectomy performed by laparoscopy. Laparoscopic gonadectomy can be performed in individuals with TS and CAIS. Different surgical strategies have to be considered for gonads in different locations. Gonadectomy by laparoscopy should be considered for these young patients with clinical, psychological, and cosmetic benefits.

Keywords: Laparoscopic; Turner Syndrome; Androgen-Insensitivity Syndrome

1. Introduction

Women with mosaic Turner syndrome (TS) bearing the presence of Y chromosome material or with complete androgen insensitivity syndrome (CAIS) are at risk of gonadal malignancy. The current recommendation is to perform gonadectomy to allow detection and prevention of the malignant change. We described in this report two cases with the characteristic features of these uncommon disorders, and in whom gonadectomy were performed successfully by laparoscopy. The surgical techniques are reviewed and discussed.

2. Objectives

The aim of the present study is to report 2 clinical cases, and review the surgical aspects of laparoscopic gonadectomy.

2.1. Case 1

A healthy 18-year-old student was visited for primary amenorrhoea. There was no galactorrhoea, excessive

hair growth or acne. On physical examination, her body height, weight and BMI were 1.53m, 52kg and 22m/kg², respectively. The breast and pubic hair showed Tanner stage II development. The external genitalia and hymen had normal findings in examination. The patient did not have sexual experience; therefore the vaginal examination was not performed. Transabdominal ultrasound examination showed the presence of uterus but the ovaries were not identified. The follicular stimulating hormone (FSH) and estrogen levels were 106 IU/l and 43pmol/l respectively, which were compatible with ovarian failure. Karyotyping showed 45X/46XY chromosomes. The diagnosis of premature ovarian failure due to Mosaic Turner syndrome was made. Due to the presence of Y chromosome, gonadectomy was advised because of the risk of malignant change. Laparoscopic gonadectomy was performed. During the operation, the uterus was present, both fallopian tubes were normal and both gonads were small and found in the lateral walls of the pelvis. The gonadectomy was performed similar to the usual laparoscopic oophorectomy, and was uncomplicated. The histo-pathological examina-

Implication for health policy/practice/research/medical education:

Women with mosaic Turner syndrome (TS) bearing the presence of Y chromosome material or with complete androgen insensitivity syndrome (CAIS) are at risk of gonadal malignancy. Two patients with characteristic features of these uncommon disorders are reported, and a review of the surgical techniques of laparoscopic gonadectomy is discussed. Laparoscopic gonadectomy can be performed; different surgical strategies have to be considered for gonads in different locations. Gonadectomy by laparoscopy should be considered for these young patients with clinical, psychological, and cosmetic benefits.

Copyright © 2013, Minimally Invasive Surgery Research Center and Mediterranean and Middle Eastern Endoscopic Surgery Association. This is an Open Access article distributed under the terms of the Creative Commons Attribution License (<http://creativecommons.org/licenses/by/3.0>), which permits unrestricted use, distribution, and reproduction in any medium, provided the original work is properly cited.

tion of the specimen showed bilateral streak gonads with ovarian stroma. There was no ovum, follicle nor testicular tissue. Regarding some reports about potential pregnancies with oocyte donation in these patients, and also there was no pathology in the uterus, hysterectomy was not indicated for the patient.

After the operation, hormone replacement therapy was advised and accepted by the patient.

2.2. Case 2

A healthy 16-year-old student presented with primary amenorrhoea. Physical examination showed that her body height, weight and BMI were 1.68 m, 59.6 kg and 21 m/kg², respectively. Breast development was in Tanner stage V. The external genitalia had normal findings in examination. There was no pubic or axillary hair seen, and there was no mass palpable along the inguinal canal. Ultrasound showed the absence of uterus. Hormonal profile showed that FSH and estrogen levels were 18.1 IU/l and 145 pmol/l respectively. The testosterone level was 23.9 nmol/l, and chromosome study confirmed 46 XY karyotype. Complete androgen insensitivity syndrome was diagnosed and the patient was advised for gonadectomy to avoid the risk of malignant change of the gonads. The patient initially declined the operation, and did not attend for follow up. She was seen again at 23 years old when she was planning for marriage and agreed for operation. Examination showed that she had blind end vagina with adequate length, and she did not have coital problem with her partner. Preoperative ultrasound and magnetic resonance imaging (MRI) of the pelvis could not identify the exact location of the gonads before the operation. The intraoperative findings are shown in Figure 1. During laparoscopy, the uterus was absent and the bilateral gonads were located at the pelvic brim. Laparoscopic gonadectomy was performed with bipolar diathermy and scissors. The operation was uncomplicated and the pathological examination of the gonads showed benign immature testes. The patient was started on estrogen replacement therapy.

3. Discussion

Turner syndrome was first described by Henry Turner in 1938. It affects approximately 3% of female conceptuses, most embryos with 45 X genetic makeup abort spontaneously or electively due to prenatal detection. It has been estimated that 1 in 2500-3000 new-born females are affected (1, 2). Classical descriptions of the syndrome include short stature, webbed neck, a low posterior hairline, a broad chest with widely spaced nipples, and cubitus valgus (3). The clinical presentation of TS varies between patients, and can be subtle especially in case of mosaicism. In a review of adult women with TS, 21% were

not diagnosed till 16 years old (4). Short stature is a consistent finding in TS. The commencement of growth hormone therapy at appropriate age is crucial for the final height attained. A high index of suspicion in girls with short stature is required to detect TS early to allow treatment. The karyotype of TS is 45 X, or the mosaic forms such as 45 X / 46 XX or 45 X / 46 XY as in this patient (2, 3). It has been estimated that there is a risk of malignancy of

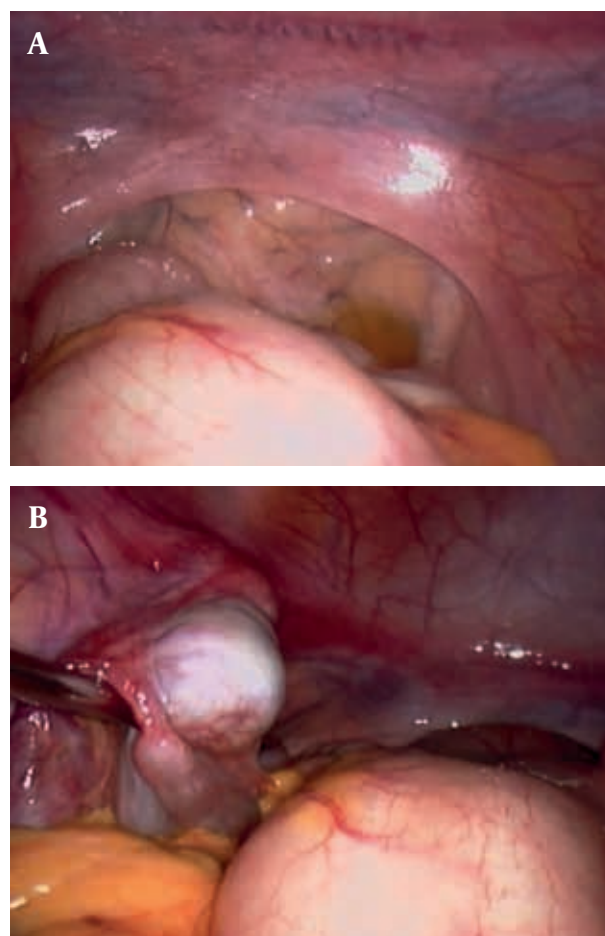


Figure 1. Absent Uterus, Gonad at Pelvic Brim in Complete Androgen Insensitivity Syndrome

the gonads in 10-30% of patients with the presence of Y chromosome material. Therefore, gonadectomy is recommended (5-9). Spontaneous pregnancies can occur in patients with mosaic TS who undergo spontaneous puberty and menstruation. There are also reports of pregnancies achieved by oocyte donation. However there are significant risks associated with pregnancy in TS including increased risks of pre-eclampsia, preterm birth and intrauterine growth restriction. The most dreaded complication is aortic dissection leading to maternal death which is approximately 2% in pregnant women with TS. Recently, the practice committee of the American soci-

ety for reproductive medicine recommended that TS is a relative contraindication for pregnancy; however, it is an absolute contraindication for pregnancy in a patient with a documented cardiac anomaly (10, 11). Complete androgen insensitivity syndrome was first described by John Morris in 1953 which was initially termed testicular feminisation syndrome. It is a rare X linked recessive disorder, affected patients can be identified within families (12, 13). The genotype is XY, but as a result of nonfunctional androgen receptor, the individuals do not develop the male phenotype. The androgen receptor (AR) gene is located on the X chromosome, with more than 800 different mutations in the AR identified (13-15). After the initial description by Morris et al, further understanding of the condition has been gained from isolated reports or series. Ahmed et al published the largest cohort of 105 cases of CAIS from their clinical registry. It was observed that the patients presented with inguinal hernia in childhood (67 %) or primary amenorrhoea (6 %). Cases were also identified by positive family history (21 %) or a mismatch between prenatal karyotyping and phenotypic sex (6 %) (16). Although more than a hundred of cases had been reviewed, the limitation is that the registry identified cases from Paediatric endocrinologists and the findings may be biased to the group who presented at childhood. The Paediatric surgeons are likely to see CAIS patients as infant girls present with inguinal hernia, and this presentation should prompt the consideration of this diagnosis with karyotyping performed. Gynaecologists are likely to see CAIS patients present with primary amenorrhoea. They have been brought up as females until puberty. The features of CAIS include normal external genitalia and breast development, minimal or absent pubic and axillary hair. The vagina is a blind pouch of variable length. There is no cervix and uterus. The gonads are testes and are located intraabdominally, at the inguinal rings, along the inguinal canal or in the labia majora (12-15). The estimated risk of gonadal malignancy has been reported to range from 0.8% to 22%, but due to the rarity of the condition and limitation of case reports or series, an accurate assessment of the malignancy risk is not available. Most of the authors recommended prophylactic gonadectomy as a prudent approach (15-19). The timing of gonadectomy is controversial. Early gonadectomy in childhood has been proposed to avoid the risk of potential malignant changes of the gonads, and reduce the distress to the CAIS patients by having the decision of gonadectomy made by the parents. Others argued for delaying gonadectomy after puberty because the observed risk of malignant change in childhood is very low and the patients can be fully informed of their conditions and involved in decision making when they are more mature. Delaying gonadectomy also allows for spontaneous puberty and avoids exogenous estrogen induction. With the paucity of data and the unknown exact risk of malignancy at dif-

ferent stages, the optimal timing of gonadectomy remains unresolved (15-19). For TS patients, the gonads are generally situated at the pelvic brim, and laparoscopic gonadectomy should be similar to the usual oophorectomy. For CAIS, the possibilities are that the gonads can be present anywhere along the course of descent. Preoperative imaging could not identify the exact location of the gonads before surgery in our patient. Our strategy was that if the gonads were not present at the pelvic brim, further dissection along the course of the descent would be required. The approach would be opening the peritoneum at the pelvic brim and identify the gonadal vessels which should be in close proximity to the ureters. Then follow the course of the gonadal vessels towards the deep inguinal ring. If the gonads were still not found, further dissection within the inguinal canal with laparoscopic grasper would be performed to expose them intraabdominally if possible. If the gonads were deep within the canal and could not be pulled intraabdominally, they would be pushed out through the superficial inguinal ring for excision. Before the era of laparoscopic surgery, the gonads were removed by laparotomy. Portuondo et al first reported the laparoscopic approach to obtain biopsy from the gonads in 1986 (20). With the development of laparoscopic management of adnexal pathologies in the early 1990s, laparoscopic gonadectomy for intraabdominally located gonads in XY females were also reported (21). Since then, more than 30 CAIS patients had successful laparoscopic gonadectomy performed without complication for intraabdominally located gonads (22-35). The procedure should be similar to the laparoscopic oophorectomy using standard laparoscopic techniques and should be considered the procedure of choice to avoid laparotomy. To the best of our knowledge, there are only three articles in the literature reporting specific surgical techniques (36-38). Kristiansen et al. reported their approach to remove the gonads located within the inguinal canals by laparoscopy. During the operation, the peritoneum overlying the ureters were incised and the gonadal vessels were identified next to the ureters and then traced to the deep inguinal rings where the ductus deferens were seen entering the rings with the vessels. The ductus deferens were then grasped and pulled out from the canal by gentle traction (36). In cases the gonads are deep within the canal or adherent, Lee et al., reported the use of digital blunt dissection technique to assist laparoscopic gonadectomy. The surgeon inserted an index finger through a 12 mm incision at the midclavicular line of the lower abdomen and palpated into the inguinal canal. The other hand was used to elevate the inguinal ring externally to assist the digital blunt dissection to free the gonads from the canal (37). Yalinkaya et al. described a method of laparoscopy-assisted transinguinal extracorporeal gonadectomy to remove the gonads by exteriorizing them at the cutaneous end of the inguinal canal

by pushing them through the canal using laparoscopic graspers (38). With the methods reported, laparoscopic gonadectomy should be feasible. However, the dissection within the inguinal canal as described may potentially weaken the inguinal area and may damage of the ilioinguinal nerve which transverse the inguinal canal. There is a lack of information on these potential complications to guide whether additional procedure to strengthen the inguinal area to prevent future hernia is required. Patients affected by the disorders face problems of sexual identity, interpersonal relationship, sexual function, fertility issues, and the long term use of hormonal replacement therapy (39, 40). The need to undergo surgery for removal of the gonads is another stressor for them (17). Using minimally invasive techniques with the benefits of earlier discharge from hospital, earlier return to social activities, and with better cosmetic outcome may increase the acceptability of gonadectomy to these groups of young patients.

Acknowledgements

There is nothing to be acknowledged.

Authors' Contribution

Dr. Alyssa Sze-Wai Wong and Dr. Pong-Mo Yuen provided input on conception and design of the paper and performed laparoscopic gonadectomy for the cases. Dr. Wong wrote the report. Dr. Yuen critically revised the manuscript for important intellectual content for submission.

Financial Disclosure

All authors have no financial interests related to the material in the manuscript.

Funding Support

The authors have no financial interests related to the material in the manuscript, and have not received any source of support / funding for this report.

References

- Critchley HOD. *Amenorrhoea and oligomenorrhoea, and hypothalamic-pituitary dysfunction*. Third edition ed. p. 229-43.
- Held KR, Kerber S, Kaminsky E, Singh S, Goetz P, Seemanova E, et al. Mosaicism in 45,X Turner syndrome: does survival in early pregnancy depend on the presence of two sex chromosomes? *Hum Genet*. 1992;**88**(3):288-94.
- Morgan T. Turner syndrome: diagnosis and management. *American family physician*. 2007;**76**(3):405-10.
- Garden A, Hernon M, Topping J. *Paediatric and Adolescent Gynaecology for the MRCOG and Beyond*. 2008.
- Canto P, Kofman-Alfaro S, Jimenez AL, Soderlund D, Barron C, Reyes E, et al. Gonadoblastoma in Turner syndrome patients with nonmosaic 45,X karyotype and Y chromosome sequences. *Cancer Genet Cytogenet*. 2004;**150**(1):70-2.
- Mazzanti L, Cicognani A, Baldazzi L, Bergamaschi R, Scarano E, Strocchi S, et al. Gonadoblastoma in Turner syndrome and Y-chromosome-derived material. *Am J Med Genet A*. 2005;**135**(2):150-4.
- Ranke MB, Saenger P. Turner's syndrome. *The Lancet*. 2001;**358**(9278):309-14.
- Bianco B, Nunes Lipay MV, Guedes AD, Verreschi ITN. Clinical implications of the detection of Y-chromosome mosaicism in Turner's syndrome: report of 3 cases. *Fertility and Sterility*. 2008;**90**(4):1197.e17-e20.
- Esegbona G, Cutner A, Cuckow P, Creighton S. Laparoscopic gonadectomy in paediatric and adolescent girls with intersex disorders. *BJOG*. 2003;**110**(2):210-2.
- Nwosu EC, Brockbank A, Walkinshaw SA. A successful pregnancy in a Turner syndrome with oocyte donation. *J Obstet Gynaecol*. 2012;**32**(5):419-21.
- Increased maternal cardiovascular mortality associated with pregnancy in women with Turner syndrome. *Fertil Steril*. 2012;**97**(2):282-4.
- Morris JM. The syndrome of testicular feminization in male pseudohermaphrodites. *Am J Obstet Gynecol*. 1953;**65**(6):1192-1211.
- Oakes MB, Eyvazzadeh AD, Quint E, Smith YR. Complete androgen insensitivity syndrome—a review. *J Pediatr Adolesc Gynecol*. 2008;**21**(6):305-10.
- Jorgensen PB, Kjartansdottir KR, Fedder J. Care of women with XY karyotype: a clinical practice guideline. *Fertil Steril*. 2010;**94**(1):105-13.
- Hughes IA, Davies JD, Bunch TI, Pasterski V, Mastroyannopoulou K, MacDougall J. Androgen insensitivity syndrome. *The Lancet*. 2008;**380**(9851):1419-28.
- Ahmed SF, Cheng A, Dovey L, Hawkins JR, Martin H, Rowland J, et al. Phenotypic features, androgen receptor binding, and mutational analysis in 278 clinical cases reported as androgen insensitivity syndrome. *J Clin Endocrinol Metab*. 2000;**85**(2):658-65.
- Deans R, Creighton SM, Liao LM, Conway GS. Timing of gonadectomy in adult women with complete androgen insensitivity syndrome (CAIS): patient preferences and clinical evidence. *Clin Endocrinol (Oxf)*. 2012;**76**(6):894-8.
- Purves JT, Miles-Thomas J, Migeon C, Gearhart JP. Complete androgen insensitivity: the role of the surgeon. *J Urol*. 2008;**180**(4 Suppl):1716-9.
- Kravarusic D, Segulier-Lipszyc E, Feigin E, Nimri R, Nagelberg N, Freud E. Androgen insensitivity syndrome: risk of malignancy and timing of surgery in a paediatric and adolescent population. *Afr J Paediatr Surg*. 2011;**8**(2):194-8.
- Portuondo JA, Neyro JL, Barral A, Gonzalez-Gorospa F, Benito JA. Management of phenotypic female patients with an XY karyotype. *J Reprod Med*. 1986;**31**(7):611-5.
- Shalev E, Zabari A, Romano S, Luboshitzky R. Laparoscopic gonadectomy in 46XY female patient. *Fertil Steril*. 1992;**57**(2):459-60.
- Tourlakis D, Schnabel J, Fersis N. Bilateral gonadal cysts and late diagnosis of androgen insensitivity syndrome treated by laparoscopic gonadectomy. *Case Rep Obstet Gynecol*. 2011;**2011**:230845.
- Kriplani A, Savithrisowmya S, Agarwal N, Garg P, Maheswari D, Ammini AC, et al. A rare case of large epididymal cyst in androgen insensitivity syndrome removed laparoscopically. *J Minim Invasive Gynecol*. 2009;**16**(4):504-6.
- Nichols JL, Bieber EJ, Gell JS. Case of sisters with complete androgen insensitivity syndrome and discordant Mullerian remnants. *Fertil Steril*. 2009;**91**(3):932 e15-8.
- Yanai Y, Hiroi H, Osuga Y, Fujimoto A, Momoeda M, Yano T, et al. Androgen insensitivity syndrome with serous gonadal cyst. *Fertil Steril*. 2008;**90**(5):2018 e9-11.
- Frishman GN. Laparoscopic gonadectomy for androgen insensitivity syndrome: karyotype tells the tale. *Am J Obstet Gynecol*. 2007;**196**(6):612 e1-2.
- Baksu A, Kabukcuoglu F, Baksu B, Goker N. Bilateral sertoli cell adenoma and serous cyst in a patient with androgen insensitivity syndrome. *Eur J Obstet Gynecol Reprod Biol*. 2004;**114**(1):104-7.
- Kallipolitis GK, Milingos SD, Creatsas GK, Deligeorgiou EK, Michalas SP. Laparoscopic gonadectomy in a patient with testicular feminization syndrome. *J Pediatr Adolesc Gynecol*. 2000;**13**(1):23-6.
- Kriplani A, Abbi M, Ammini AC, Kriplani AK, Kucheria K, Takkar D. Laparoscopic gonadectomy in male pseudohermaphrodites. *Eur J Obstet Gynecol Reprod Biol*. 1998;**81**(1):37-41.
- Obianwu CW, Palter SF, Bruno AA, Jr. Bilateral laparoscopic gonadectomy in a patient with complete androgen insensitivity. A case report. *J Reprod Med*. 1996;**41**(4):270-2.

31. Diaz DG, Chavez-Lopez D. Laparoscopic gonadectomy in a woman with complete androgen insensitivity syndrome. *J Am Assoc Gynecol Laparosc.* 1996;**3**(2):317-9.
32. Qasim SM, Sachdev R. Laparoscopic bilateral gonadectomy in a phenotypic woman with a form of Leydig cell hypoplasia. *J Am Assoc Gynecol Laparosc.* 1996;**3**(2):313-6.
33. Corsan GH, Jow W, Karacan M, Qasim S. Laparoscopic gonadectomy in complete androgen insensitivity syndrome. *J Am Assoc Gynecol Laparosc.* 1994;**2**(1):87-9.
34. Batzer FR, Nelson JR, Corson SL, Gocial B. Laparoscopic approach to definitive treatment of androgen insensitivity syndrome. A case report. *J Reprod Med.* 1994;**39**(7):541-3.
35. Chantilis SJ, McQuitty DA, Preminger GM, Marshburn PB. Laparoscopic removal of gonads containing on occult seminoma in a woman with complete androgen resistance. *J Am Assoc Gynecol Laparosc.* 1994;**1**(3):277-82.
36. Kristiansen SB, Doody KJ. Laparoscopic removal of 46XY gonads located within the inguinal canals. *Fertil Steril.* 1992;**58**(5):1076-7.
37. Lee RM, Peterson CM, Kreger DO, Chambers CE, Case KE. Digital blunt dissection technique to assist laparoscopic gonadectomy in inguinally located/adhered gonads. *J Laparoendosc Surg.* 1993;**3**(3):229-32.
38. Yalinkaya A, Yayla M. Laparoscopy-assisted transinguinal extracorporeal gonadectomy in six patients with androgen insensitivity syndrome. *Fertil Steril.* 2003;**80**(2):429-33.
39. El Saman AM, Ismael AM, Zakherah MS, Nasr A, Tawfik RM, Bedaiwy MA. Enhancement balloon vaginoplasty for treatment of blind vagina due to androgen insensitivity syndrome. *Fertil Steril.* 2011;**95**(2):779-82.
40. Minto CL, Liao KL, Conway GS, Creighton SM. Sexual function in women with complete androgen insensitivity syndrome. *Fertil Steril.* 2003;**80**(1):157-64.