

# Totally Extraperitoneal Endoscopic Inguinal Hernia Repair Using Mini Instruments: Pushing the Boundaries of Minimally Invasive Hernia Surgery

Marcelo de Paula Loureiro<sup>1,\*</sup>, Pedro Trauczynski<sup>1</sup>, Christiano Claus<sup>1</sup>, Gustavo Carvalho<sup>1,2</sup>, Eduardo Bonin<sup>1</sup>, Leandro Cavazzola<sup>3</sup>

<sup>1</sup> Minimally Invasive Surgery of Jacques Perissat Institute, Positivo University, Curitiba, Brazil

<sup>2</sup> Federal University of Pernambuco, Recife, Brazil

<sup>3</sup> Federal University of Rio Grande Do Sul, Porto Alegre, Brazil

\*Corresponding author: Marcelo de Paula Loureiro, Rua Angelo Bom 315, P.O. Box: 81210340, Curitiba, Brazil. Tel: +5541-91989610, Fax: +5541-32596799, E-mail: mpailoureiro@gmail.com.

## ABSTRACT

**Background:** Inguinal hernia is the most prevalent surgical disease in clinical practice. Endoscopic inguinal hernia repair has been shown to be slightly superior to open approaches. Recent modifications in the minilaparoscopic technique may improve the totally extraperitoneal repair (TEP) results.

**Objectives:** We have performed a prospective study to analyze the feasibility of laparoscopic inguinal hernia repair using mini instruments. Main measured outcomes included postoperative pain, return to work activities and aesthetics. Technical aspects, including operative time and intraoperative and postoperative complications were also analyzed.

**Patients and Methods:** From October, 2009 to May, 2011 consecutive patients undergoing TEP inguinal hernia repair using mini-instruments were included in the study protocol. Exclusion criteria was the same as for standard laparoscopic hernia repair. In all cases, a standardized laparoscopic technique using mini instruments was performed. A study protocol was applied prospectively for data collection, including operative time, hospital stay, need for pain medication, return to work and, patient's aesthetic evaluation of the scars. Results were expressed in Mean  $\pm$  SD.

**Results:** Sixty consecutive patients diagnosed with inguinal hernia underwent TEP inguinal hernia repair using mini instruments. Of these, 53 were men and seven were women. The mean age was  $50 \pm 32$  years. In eight cases, the hernias were recurrent and ten were bilateral. A total of 70 hernias were treated. The average operative time was  $\pm 35$  min. The mean hospital stay was  $18 \pm 6$  hours. Analgesia was necessary for more than 2 days in 8 patients (13.3 %). There was one conversion to open surgery. Sixteen of the male workers (37 %) had to take 1 week off work. In total, 58 (96 %) of the patients considered the aesthetic outcome to be excellent. Patients were followed for 30 days. No recurrences were noted in this period.

**Conclusions:** Totally extraperitoneal endoscopic inguinal hernia repair using mini instruments is feasible, and applicable to routine surgical practice with good short-term clinical and aesthetic results. Further comparative studies with standard laparoscopic extraperitoneal and open hernia repair are needed to access its long term results.

**Keywords:** Abdominal, Hernia; Instruments

►Article type: Research Article; Received: 14 Dec 2012; Revised: 14 Dec 2012; Accepted: 19 Dec 2012; Epub: 30 June 2013;

►Implication for health policy/practice/research/medical education:  
To add some possible technical developments to endoscopic hernia repair.

►Please cite this paper as:

de Paula Loureiro M, Trauczynski P, Claus C, Carvalho G, Bonin E, Cavazzola L. Totally Extraperitoneal Endoscopic Inguinal Hernia Repair Using Mini Instruments: Pushing the Boundaries of Minimally Invasive Hernia Surgery. J Minim Invasive Surg Sci. 2013; 2(3): 8-12.

►Copyright © 2013, Minimally Invasive Surgery Research Center and Mediterranean and Middle Eastern Endoscopic Surgery Association.

This is an Open Access article distributed under the terms of the Creative Commons Attribution License (<http://creativecommons.org/licenses/by/3.0>), which permits unrestricted use, distribution, and reproduction in any medium, provided the original work is properly cited.

## 1. Background

Inguinal hernia is the most prevalent surgical disease in clinical practice. It is estimated that 20 million inguinal hernia procedures are performed each year (1), and the risk of recurrence is 27 % for men and 3 % for women (2). While the best surgical approach for inguinal hernia continues to be debated among surgeons, endoscopic hernia repair has become widely used since the 1990s (3-5). Currently, endoscopic hernia repair is performed by using one of two so-called posterior approaches, namely, the totally extraperitoneal (TEP) and the transabdominal (TAPP) approaches. These techniques are based on the preperitoneal repair concept developed by Stoppa (6). These posterior approaches utilize a large mesh that covers the myopectineal orifice at the preperitoneal layer of the fascia transversalis. Over the years, endoscopic hernia repair has been shown to be slightly superior to open approaches, mainly because it is associated with an earlier recovery, less chronic pain, and a lower risk of infection (7). However, these endoscopic techniques are not unanimously accepted and several issues still prevent its widespread usage, including the fact that the cost of the procedure is higher, it is difficult to learn, and it carries the risk of severe complications (8, 9). In order to simplify the procedure and reduce costs, avoidance of dissecting balloons and fixation has been advocated. Apart from these improvements some efforts that have been made to develop minimally invasive surgical technics in general. These efforts have led to the development of several novel access and procedures which have in common reducing operative ports and surgical incisions and consequently, its complications. These techniques include Natural Orifice Surgery Transluminal Endoscopic Surgery (NOTES), and Reduced Port Surgery (also known as single port, single access, single site surgery). Minilaparoscopic (or needlescopic) surgery is not as recent as the above-mention procedures, but it has recently regained considerable attention for reducing surgical scars while maintaining virtually all technical aspects related to laparoscopy. Recent modifications in the minilaparoscopic technique, such as using 0-degree laparoscopes (instead of the usual 3 mm fragile endoscopes) and 2 - 3 mm instruments (10), may add some advantages to the TEP technique. Nowadays, such a less invasive technique may be especially useful because of a high demand for better esthetic outcomes that became usual after the advent of the NOTES "hype". The efficacy of this approach has been tested in pediatric patients, where it was used to repair the internal inguinal orifice (11, 12). In the present study, a prospective series of consecutive adult patients who underwent minilaparoscopic TEP hernia repair, without the use of a balloon dissector or mesh fixation, is reported.

## 2. Objectives

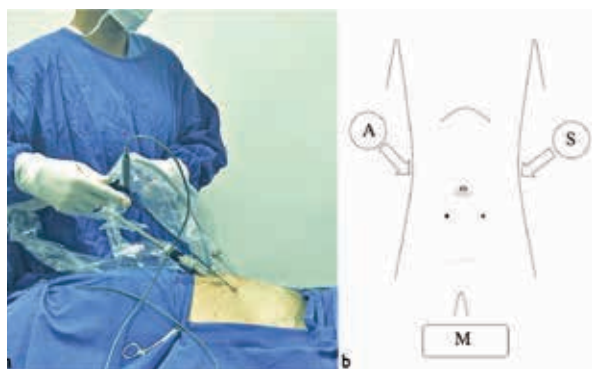
We performed a prospective study to analyze the feasibility of laparoscopic inguinal hernia repair using mini instruments. Main measured outcomes included postoperative pain, return to work activities and aesthetics. Technical aspects, including operative time and intraoperative and postoperative complications were also analyzed.

## 3. Patients and Methods

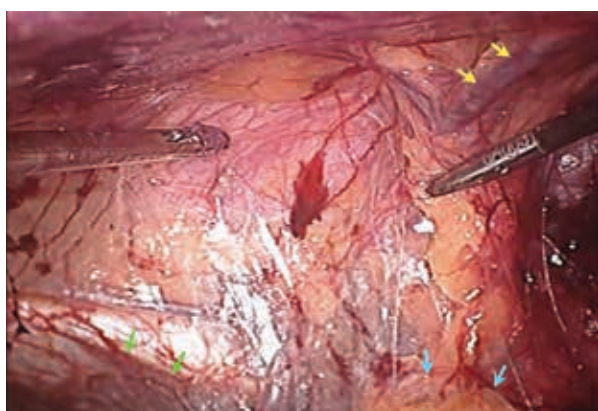From October 2009 to May 2011, patients diagnosed with inguinal hernia underwent TEP inguinal hernia repairs with mini instruments. An exclusion criterion was patients with no clinical condition to be submitted to general anesthesia and multiple abdominal scars in the hypogastric region. All inguinal hernias were classified according to Nyhus classification (13). A protocol was applied prospectively for data collection, evaluating operative time in minutes, hospital stay in days, need for pain control medication in number of pain medications and return to work in weeks. Patients were asked to evaluate the aesthetic aspect of the scars rating them as excellent, good, fair or bad after at least 1 week following surgery. All patients signed an informed consent form that detailed the basic technique and highlighted the difference from the usual TEP surgical procedure in the sense that more delicate instruments would be used. Patients were evaluated postoperatively 1, 2 and 4 weeks after surgery.

### 3.1. Operative Technique

In all cases, a standardized laparoscopic technique using mini instruments was performed. General anesthesia was used routinely. The extraperitoneal space was obtained by suprapubic puncture with a Verres needle and injection of CO<sub>2</sub> in the space of Retzius, as described by Dulucq (3). This technique obviates the use of balloon dissection. The 10 mm trocar for the rigid endoscope was then inserted into the previously distended space. Thereafter, under direct view, two minilaparoscopic trocars [2.8 mm and 3.6 mm (Bhiosuply, Pillar, RS, Brazil)] were placed symmetrically 4 cm inferiorly and laterally to the 10 mm trocar, thereby respecting the triangulation principle (Figure 1). Special care was taken not to injure the epigastric vessels. For the dominant hand, we chose a 3.6 mm trocar, which allows the passage of insulated instruments. The dissection of direct and indirect hernias was performed in a standard manner. Inguino scrotal hernias were technically more difficult and sometimes required section of the hernia sac. Once the anatomical elements were properly identified (Figure 2), including the dissection of the peritoneum that covers the floor of the anterior pelvic wall, a 14 × 11 cm polypropylene mesh was placed without fixation.



**Figure 1.** The Placement of The Minitrocars for Either Unilateral or Bilateral Procedures

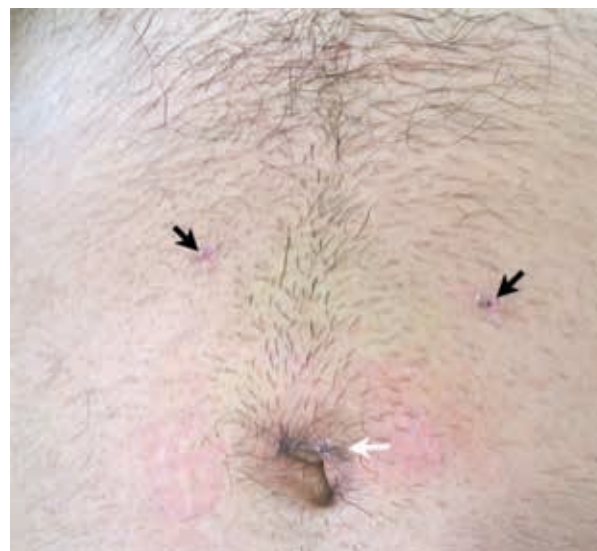

**Figure 2.** Laparoscopic Inguinal Hernia Repair (Right Side) Using Mini Instruments. Endoscopic View of Anatomical Landmarks: Epigastric Vessels (Yellow Arrows), the External Iliac Vein (Green Arrows), and Direct Right Hernia, Already Dissected Towards the Bottom (Blue Arrows)

#### 4. Results

Sixty patients were included in the study protocol. Of these, 53 were men and seven were women. The mean age was 50 ( $\pm 32$ ) years. In eight cases, the hernias were recurrent and ten were bilateral. In total, 70 hernias were treated. According to the Nyhus hernia classification, 27 were type II, 17 were type IIIA, 16 were type IIIB, two were type IIIC, and eight were recurrent (type IV) hernias. None of these consecutive patients met exclusion criteria. All others, even with midline incision for previous prostatectomy (2 patients) were included. The average operative time was 54 ( $\pm 35$ ) min. There were no intraoperative complications such as bleeding or injury of the bladder. There were perforation of the peritoneum in six patients (10 %), four of them did not alter the operative time. In two cases, it was necessary to place a mini 2.8 mm trocar into the peritoneal cavity to relieve excessive pressure and allow completion of the procedure. Conversion to conventional laparoscopy then to open surgery was required in one case due to technical difficulty (lack of

proper working space) in a recurrent hernia. The mean hospital stay was 18 ( $\pm 6$ ) hours. Regarding post operative pain, all patients were instructed to take on-demand pain killers (nimesulide 100 mg orally) after discharge. Analgesia was necessary for more than 2 days only in 8 patients (13.3 %). The remaining patients reported no pain after this period. Seroma formation was observed in ten patients (16 %); a persistent seroma was seen in two of these patients for more than four weeks, but there was no need for drainage. There were no recurrences during the 4-week follow-up period. Of the male patients, 44 were active workers (83 %); the remaining nine were retired. Sixteen (37 %) of the male workers took just 1 week off work, while the remaining 28 (63 %) took 2 weeks off. One of the women was an active worker and stayed away from her professional activities for 10 days. When asked about the aesthetic outcome, 58 (96 %) of the patients considered it to be excellent. Only two rated it as merely good. (Figure 3).



**Figure 3.** Aesthetic Outcome of Minilaparoscopic Incisions for the Repair of an Inguinal Hernia, One Week After Surgery. Note Two Small Punctiform Scars Corresponding to the Mini Trocars (Black Arrows) and a Longitudinal Scar at the Level of the Umbilicus Corresponding to a 10 mm Laparoscopic Trocar (White Arrow)


#### 5. Discussion

In the 13 years since we started using the TEP technique in Brazil, we have chosen not to use disposables because it seemed wasteful and expensive. This decision is supported by other surgical teams who have considerable experience with the technique (13-18). Not using fixation and opening the extraperitoneal space without using a balloon also allows this surgical approach to be more competitive in terms of hospital costs, and less likely to cause chronic pain (8, 14, 16-19). However, it remains difficult to increase the popularity of TEP, even though it has been



demonstrated to be as safe and to have as good or even better results than other techniques. The main factors for TAPP and TEP techniques for remaining restricted to a few number of surgeons are economical issues, longer learning curve, the possibility of major complications and the type of anesthesia needed. Some studies suggests that the learning curve for TEP can vary from 80 to 250 surgeries (20, 21). This seems to us to be an overestimation. We believe the TEP technique should not be restricted only to difficult cases such as recurrent and bilateral hernias, but also practiced routinely in order to increase experience, and, therefore, expertise. Performing TEP properly also requires a precise anatomical knowledge of the anterior pelvic wall and good surgical skills. TEP is usually performed with 5 mm instruments, which may be too thick for such a restricted workspace. Moreover, the trocars are positioned very close to each other and to the object of dissection as well. This set of ergonomic circumstances means that the procedure is quite difficult to execute. Any space that is gained by gentle dissection with adequate hemostasis, associated with smaller volume occupied by the mini instruments (Figure 4), can help to make it easier. The new low-friction mini trocars also facilitate the operation by allowing the laparoscopic gestures to be performed with less force and more precision. Thus, the mini instruments together with low-friction mini trocars seem to be perfect for small space surgical procedures such as preperitoneal operations. If a surgeon who is interested in this type of repair has had good training and has technically mastered mini instruments, it should not be difficult to acquire the necessary skills for TEP and quickly progress in the learning curve. Although the present study did not compare the outcomes of TEP with mini instruments with those of conventional laparoscopy, its results suggest that the use of mini instruments is associated with aesthetic benefits as well as greater technical precision. This assumption is accordance with other authors, who pointed out difficulties such as the fragility of the instrument, the lack of triangulation of the trocars, and the impossibility of dissecting inguino scrotal hernia sacs (22). It is undoubtedly true that repairing inguino scrotal hernias by TEP with mini instruments is challenging, similar to when conventional laparoscopic TEP is used. As our patients were not selected, we encountered several very technically difficult cases in the 16 (26 %) cases of Nyhus type IIIB hernias. Although we always try to dissect the peritoneal sac of indirect hernias completely, if it becomes extremely difficult to do so, we cut it as distally as possible. As a result, in general, it is not necessary to close the peritoneal hole that is created because it is obliterated by the redundancy of the sac. Notably, the mean procedure duration for the 432 cases of TEP with 5 mm instruments that we performed over the last 12 years was 50 minutes; of these cases, perforation of the peritoneum occurred in 22 %. After we started to use mini instruments,

the mean surgery duration did not change (54 min) but the number of perforations decreased to 10 %. Overall, the results of our study shows that totally extraperitoneal inguinal repair using mini instruments is feasible in routine surgical practice. The hernia surgery parameters that were evaluated in the present study were the level of pain experienced, the aesthetic outcome, and the ability to return quickly to routine activities, rather than the recurrence rate. This is because our patients were only followed for a short period (4 weeks) and thus recurrence could not be properly evaluated. The addition of minilaparoscopy to the TEP surgical procedure seemed to have added benefits with regard to pain, aesthetic outcome, and recovery time, although we did not perform a comparative study with the standard endoscopic technique. Studies comparing conventional laparoscopic TEP with open repair shows only a slightly advantage for in post-operative pain (10, 11). None of the patients were unhappy about the aesthetic appearance of their scars since they were minimal. The postoperative pain also did not seem to bother these patients since only 13% required analgesia for more than 2 days. The procedure was also associated with an early return to routine activities, which is another advantage of TEP (7). Indeed, most patients who underwent TEP were able to return to work within 1 to 2 weeks (83 %). However, it was also not possible to determine the specific impact of minilaparoscopy on the recovery rate in this study. In conclusion, TEP hernia repair using mini instruments is feasible in consecutive patients, since one have overcome the learning curve with conventional 5 mm instruments. This technique seems to enhance visualization and ergonomics, important features which may facilitate its widespread use. It also seems to have the potential to improve some existing strengths of conventional TEP, especially a better aesthetic outcome.



**Figure 4.** Simulation of an Endoscopic Operative Field Occupied by Standard Laparoscopic Instruments (a) Compared to Mini Instruments (b)

## Acknowledgements

The author thanks the Vitoria Hospital of Curitiba for the institutional support.

## Authors' contribution

The authors Dr. Marcelo Loureiro, Eduardo Bonin, Chris-

tiano Claus, Pedro Trauczynski, Dr. Gustavo Carvalho and Dr. Leandro Cavazolla confirm that the work presented in this research has been performed and interpreted solely by them. They also confirm that it has not been submitted elsewhere in any other form.

## Financial Disclosures

Dr. Marcelo Loureiro, Eduardo Bonin, Christiano Claus and Pedro Trauczynski has no conflicts of interest or financial ties to disclose. Dr. Gustavo Carvalho is consultant of Karl Storz and is on the speakers' bureau of Silimed. Dr. Leandro Cavazolla is consultant of Covidien and Gore. He is also part of the Advisory Board of Davos. None of these activities of Drs. Gustavo Carvalho neither Dr. Cavazolla's has any conflict of interest within the results of these paper.

## Funding/Support

None declared

## References

1. Bay-Nielsen M, Kehlet H, Strand L, Malmstrom J, Andersen FH, Wara P, et al. Quality assessment of 26,304 herniorrhaphies in Denmark: a prospective nationwide study. *Lancet*. 2001;**358**(9288):1124-8.
2. Kingsnorth A, LeBlanc K. Hernias: inguinal and incisional. *Lancet*. 2003;**362**(9395):1561-71.
3. Dulucq JL. Traitement des hernies de L'aïne par mis em place d'un patch prothetique sous-péritoneale em rétroperitonéoscopie. *Cah Chir*. 1991;**79**:15-6.
4. McKernan JB, Laws HL. Laparoscopic repair of inguinal hernias using a totally extraperitoneal prosthetic approach. *Surg Endosc*. 1993;**7**(1):26-8.
5. Phillips EH, Carroll BJ, Fallas MJ. Laparoscopic preperitoneal inguinal hernia repair without peritoneal incision. Technique and early clinical results. *Surg Endosc*. 1993;**7**(3):159-62.
6. Stoppa R, Petit J, Abourachid H, Henry X, Duclaye C, Monchaux G, et al. [Original procedure of groin hernia repair: interposition without fixation of Dacron tulle prosthesis by subperitoneal median approach]. *Chirurgie*. 1973;**99**(2):119-23.
7. Simons MP, Aufenacker T, Bay-Nielsen M, Bouillot JL, Campanelli G, Conze J, et al. European Hernia Society guidelines on the treatment of inguinal hernia in adult patients. *Hernia*. 2009;**13**(4):343-403.
8. Khajanchee YS, Kenyon TA, Hansen PD, Swanstrom LL. Economic evaluation of laparoscopic and open inguinal herniorrhaphies: the effect of cost-containment measures and internal hospital policy decisions on costs and charges. *Hernia*. 2004;**8**(3):196-202.
9. Schneider BE, Castillo JM, Villegas L, Scott DJ, Jones DB. Laparoscopic totally extraperitoneal versus Lichtenstein herniorrhaphy: cost comparison at teaching hospitals. *Surg Laparosc Endosc Percutan Tech*. 2003;**13**(4):261-7.
10. Ferzli G, Sayad P, Nabagiez J. Needlescopic extraperitoneal repair of inguinal hernias. *Surg Endosc*. 1999;**13**(8):822-3.
11. Lau H, Lee F. A prospective comparative study of needlescopic and conventional endoscopic extraperitoneal inguinal hernioplasty. *Surg Endosc*. 2002;**16**(12):1737-40.
12. Saranga Bharathi R, Arora M, Baskaran V. Minimal access surgery of pediatric inguinal hernias: a review. *Surg Endosc*. 2008;**22**(8):1751-62.
13. Dulucq JL, Wintringer P, Mahajna A. Laparoscopic totally extraperitoneal inguinal hernia repair: lessons learned from 3,100 hernia repairs over 15 years. *Surg Endosc*. 2009;**23**(3):482-6.
14. Nyhus LM, Klein MS, Rogers FB, Kowalczyk S. Inguinal hernia repair. *Types, patient care. AORN J*. 1990;**52**(2):292-304.
15. Garg P, Rajagopal M, Varghese V, Ismail M. Laparoscopic total extraperitoneal inguinal hernia repair with nonfixation of the mesh for 1,692 hernias. *Surg Endosc*. 2009;**23**(6):1241-5.
16. Khajanchee YS, Urbach DR, Swanstrom LL, Hansen PD. Outcomes of laparoscopic herniorrhaphy without fixation of mesh to the abdominal wall. *Surg Endosc*. 2001;**15**(10):1102-7.
17. Ferzli GS, Frezza EE, Pecoraro AM, Jr, Ahern KD. Prospective randomized study of stapled versus unstapled mesh in a laparoscopic preperitoneal inguinal hernia repair. *J Am Coll Surg*. 1999;**188**(5):461-5.
18. Tamme C, Scheidbach H, Hampe C, Schneider C, Kockerling F. Totally extraperitoneal endoscopic inguinal hernia repair (TEP). *Surg Endosc*. 2003;**17**(2):190-5.
19. Tam KW, Liang HH, Chai CY. Outcomes of staple fixation of mesh versus nonfixation in laparoscopic total extraperitoneal inguinal repair: a meta-analysis of randomized controlled trials. *World J Surg*. 2010;**34**(12):3065-74.
20. Lau H, Patil NG, Yuen WK, Lee F. Learning curve for unilateral endoscopic totally extraperitoneal (TEP) inguinal hernioplasty. *Surg Endosc*. 2002;**16**(12):1724-8.
21. Voitk AJ. The learning curve in laparoscopic inguinal hernia repair for the community general surgeon. *Can J Surg*. 1998;**41**(6):446-50.
22. She WH, Lo OS, Fan JK, Poon JT, Law WL. Needlescopic totally extraperitoneal hernioplasty for unilateral inguinal hernia in adult patients. *Asian J Surg*. 2011;**34**(1):23-7.