



## Laparoscopic Splenectomy for Isolated Splenic Hydatid Cyst: Why Should it Be Done?

Ritesh Pathak<sup>1</sup>, Deborshi Sharma<sup>1\*</sup>, Kamal Yadav<sup>1</sup>, Atul Goel<sup>2</sup>, Romesh Lal<sup>1</sup>

<sup>1</sup> Department of Surgery, Lady Hardinge and Associated Dr. Ram Manohar Lohia Hospital, New Delhi, India

<sup>2</sup> Department of Medicine, Lady Hardinge and Associated Dr. Ram Manohar Lohia Hospital, New Delhi, India

### ARTICLE INFO

Article type:  
Case Report

Article history:  
Received: 30 Apr 2012  
Revised: 30 May 2012  
Accepted: 28 Jul 2012

Keywords:  
Spleen  
Echinococcosis  
Laparoscopy

### ABSTRACT

**Background:** Hydatid cyst, a zoonosis caused by *Echinococcus granulosus*, is the only recognized parasitic cysts of the spleen and is known to be at least twice as common as the non-parasitic variety.

**Case Presentation:** A 35 year old woman presented with a one-year history of dull pain and a dragging sensation in her left hypochondrium. Ultrasonography revealed a hydatid cyst in the lower part of the spleen. Laparoscopic splenectomy along with hydatid cyst was done. Her post-operative phase was uneventful.

**Conclusions:** Here, we discuss the pathogenesis of the rare entity of splenic hydatid cysts and the various treatment options available.

### ► Implication for health policy/practice/research/medical education:

This article will have high implication on health care management. As splenic hydatid is rare, its standard treatment is not available. However, this will show that laparoscopic splenectomy could be safe in such cases.

### ► Please cite this paper as:

Pathak R, Sharma D, Yadav K, Goel A, Lal R. Laparoscopic Splenectomy for Isolated Splenic Hydatid Cyst: Why Should it Be Done? *J Minim Invasive Surg Sci.* 2013;2(2): 154-6. DOI: 10.5812/jmiss.5371

## 1. Background

Cysts in the spleen are a rather rare, which are further divided into parasitic and non-parasitic cysts. Hydatid cysts of the spleen are the only recognized parasitic cysts and are known to be at least twice as common as the non-parasitic variety (1). Hydatidosis/Echinococcosis is a zoonosis occurring in endemic areas. Infection is spread by contact with infected sheep and dogs and is commonly found along the northern belt of India from Kashmir to Uttar Pradesh and Bihar (2). The reported incidence of hydatid disease of the spleen ranges between 3.5 to 5.8% (2-4), making it a relatively

uncommon finding and also, because the presentation varies from completely asymptomatic incidental detection to left hypochondrial pain with dragging sensation. Spleen is the third commonest site for hydatidosis after the liver (commonest) and the pulmonary filter (2).

## 2. Case Presentation

A 35 year-old female resident of Uttar Pradesh in India presented with a pain in her left hypochondrium for nearly a year which was dull and dragging in nature. There was no accompanying history of jaundice, ecchy-

\* Corresponding author: Deborshi Sharma, Qr17, Type V, Block 3, Lodhi Road Complex, New Delhi, 110001, India. Tel: +91-1124653465, E-mail: deborshi\_sh@yahoo.com

DOI: 10.5812/jmiss.5371

© 2013 Minimally Invasive Surgery Research Center and Mediterranean & Middle Eastern Endoscopic Surgery Association.

This is an Open Access article distributed under the terms of the Creative Commons Attribution License (<http://creativecommons.org/licenses/by/3.0>), which permits unrestricted use, distribution, and reproduction in any medium, provided the original work is properly cited.

mosis, rashes, hematemesis, melena, constipation or diarrhea, cough or any urinary complaints. She worked as a field labour with her husband and children on a paddy farm. A transabdominal ultrasonography revealed an enlarged spleen with a well-defined lesion of  $7.3 \times 6.7$  cm with a floating membrane in its lower pole. A contrast enhanced computed tomography (CECT) revealed a large splenic cyst  $8.5 \times 7.5$  cm with enhancement and septations with focal mural calcifications suggestive of splenic hydatid cyst with possible superadded infection (Figure 1). Pancreas, Liver, Bowel loops and bladder were all normal. Her hematological parameters were within normal limits. Albendazole tablets were prescribed for 21 days without any clinical and radiological improvement. Hence, a surgical option was contemplated.

### 2.1. Our operative technique

Patient was operated in a left lateral leaning position with four ports. First, a diagnostic laparoscopy was done which showed two big 1 cm + splenoculi in the greater omentum. Spleen was enlarged to one and half times of its original size with dense perisplenic adhesions along with a cyst of  $10 \times 8$  cm in the lower part of the spleen. Considering the accessory spleens, a decision to do total splenectomy was taken. Greater omentum was opened and splenic artery was identified and ligated to the superior border of pancreas. The cyst had a bosselated surface which was dissected from the splenophrenic and spleno-renal ligaments. The splenic pedicle was stapled with endo stapler and the short gastric was ligated. Omentum and transverse colon was found adherent to inferior pole of spleen overlying the cyst and it was dissected and separated with ultrasonic scissors (Figure 2). The lateral attachments of the spleen were dissected and the whole spleen (Figure 3) along with hydatid cyst was taken out via Pfannenstiel incision after inserting an endobag. She had an uneventful recovery and was absolutely symptom free six months after surgery.

### 3. Discussion

Hydatid disease in humans occurs as a result of infection by the larval stages of taeniid cestodes of the genus *Echinococcus*. Certain human activities (i.e. the widespread rural practice of feeding dogs the viscera of home-butchered sheep) facilitate transmission of the sheep strain and consequently raise the risk of humans getting infected (3). Hydatid cysts of the spleen are the only recognized parasitic cysts and are known to be at least twice as common as the non-parasitic variety (1). Systemic dissemination and intra-peritoneal spread from a ruptured liver cyst are the potential theories behind development of splenic hydatid cysts. The embryo is embolized in the periphery of splenic capillaries. The incompressible mass of the cyst gradually crushes the segmentary vessels, with extensive pericys-

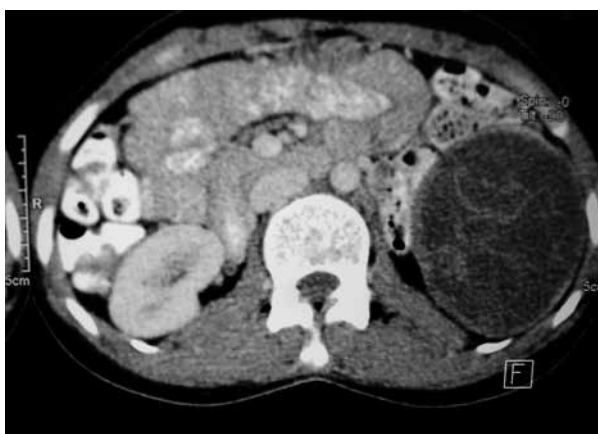

Figure 1. Harmonic Scalpel Used in Dissecting the Cyst From Lateral Wall

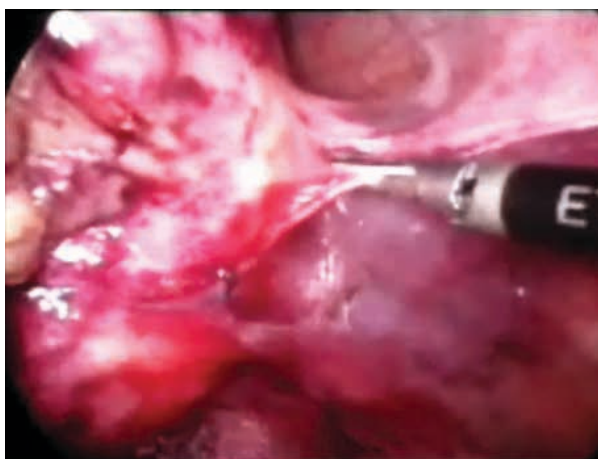


Figure 2. Complete Spleen With Cyst After Removal

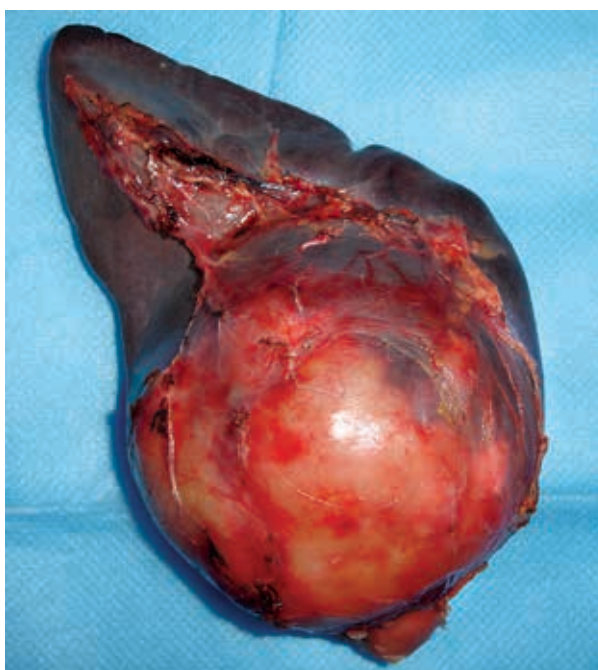


Figure 3. Removed Specimen of Spleen Showing the Large Intact Cyst in the Lower Pole

tic atrophy and resulting in regional necrotic zones. This aseptic inflammation of the splenic parenchyma extends to outside the splenic capsule, resulting in formation of adhesions to adjacent anatomic structures, (i.e., stomach, colon, omentum and diaphragm). This situation can predispose to accidental rupture of the cyst into adjacent organs which is mostly reported to the colon (4-7). There is no gold standard to diagnose hydatid disease of spleen as both serological and radiological methods are used. Radiology relies on direct visualization of the parasitic cyst while serology on the immunological response (8). Some physicians consider surgery with total conservative splenectomy as the gold standard treatment for hydatid cyst spleen (9). Many researchers have suggested that splenectomy should be the preferred treatment of hydatid cysts, but partial cystectomy is suitable when the cysts are located at the margins of the spleen (10, 11). The splenic cyst is evacuated using a large-gauge sump drain and the residual cavity is filled with a 15% saline solution. These techniques should only be used for small superficial cysts, cysts localized in one pole of the spleen, or cysts that are unresectable due to extensive adhesions. Laparoscopic partial splenectomy is a hemorrhagic operation because vascular controlling is difficult when incising the splenic tissue, whereas only unroofing the cyst wall leads to a pericystic layer and a residual cavity behind, which carries a high risk of postoperative infection (8). The disadvantages of partial splenectomy are addressed by total splenectomy, but it is not without its own set of issues. The risk of total splenectomy lies with rupture of the cyst and spillage, particularly during extraction of the specimen leading to anaphylactic reactions, leads to post splenectomy sepsis due to overwhelming infections with encapsulated bacteria (12). Drug therapy with albendazole and mebendazole are considered adjuncts to surgical treatment. Newer chemotherapies and methods such as PAIR (puncture, aspiration, injection, re-aspiration) using hypertonic saline or 0.5% silver nitrate tend to kill daughter cells but have been found to have only moderate efficacy and their usefulness is restricted (13).

#### 4. Conclusions

Splenic hydatid cyst should be suspected in patients

from endemic areas and laparoscopic cystadenectomy, partial splenectomy or total splenectomy should be considered as the preferred treatment.

#### Acknowledgements

None declared.

#### Authors' Contribution

None declared.

#### Financial Disclosure

No financial disclosure.

#### Funding/support

No Funding.

#### References

1. Franquet T, Montes M, Lecumberri FJ, Esparza J, Bescos JM. Hydatid disease of the spleen: imaging findings in nine patients. *AJR Am J Roentgenol.* 1990;**154**(3):525-8.
2. Wani I, Wani S, Baba A, Khanday Z, Bhat N, Shera A, et al. Primary calcified hydatid of spleen: a case report. *Int J Med Update.* 2010;**5**(2):68-70.
3. Moro P, Schantz PM. Echinococcosis: a review. *Int J Infect Dis.* 2009;**13**(2):125-33.
4. Uriarte C, Pomares N, Martin M, Conde A, Alonso N, Bueno MG. Splenic hydatidosis. *Am J Trop Med Hyg.* 1991;**44**(4):420-3.
5. Bourgeon R, Catalano H, Pantin JP. L'échinococcose splénique. *J Chir.* 1960;**80**:608-32.
6. Sapkas A, Tierris E. Complication spectaculaire d'un kyste hydatique géant de la rate. *J Chir (Paris).* 1972;**103**:283-6.
7. Caballero P, Ocon E, Robledo A, Díaz F. Splenic hydatid cyst opening. *AJR Am J Roentgenol.* 1986;**174**(4):859-60.
8. Torgerson PR, Deplazes P. Echinococcosis: diagnosis and diagnostic interpretation in population studies. *Trends Parasitol.* 2009;**25**(4):164-70.
9. Bhatnagar V, Agarwala S, Mitra DK. Conservative surgery for splenic hydatid cyst. *J Pediatr Surg.* 1994;**29**(12):1570-1.
10. Dar MA, Shah OJ, Wani NA, Khan FA, Shah P. Surgical management of splenic hydatidosis. *Surg Today.* 2002;**32**(3):224-9.
11. Safioleas M, Misiakos E, Manti C. Surgical treatment for splenic hydatidosis. *World J Surg.* 1997;**21**(4):374-7; discussion 8.
12. Meimarakis G, Grigolia G, Loehe F, Jauch KW, Schauer RJ. Surgical management of splenic echinococcal disease. *Eur J Med Res.* 2009;**14**(4):165-70.
13. Schwartz SI, Maingot R, Ellis H, Husser WC. *Maingot's abdominal operations.* 9th ed. Michigan: Appleton & Lange; 1989. p. 1534-45.