



A Novel Technique for Managing Complicated Branchial Cyst

Costa Healy^{1*}, Anies Mahomed¹

¹Department of Paediatric Surgery, Royal Alexandra Children's Hospital, Brighton, UK

ARTICLE INFO

Article type:
Case report

Article history:

Received: 01 Mar 2012
Revised: 02 Apr 2012
Accepted: 13 Apr 2012

Keywords:

Branchioma
Cystectomy
Inflammation

ABSTRACT

In this study we present successful management of an inflamed branchial cyst by stripping the inner lining thus providing a safe and definitive treatment. We believe that this is the first report of this technique in the literature.

► Implication for health policy/practice/research/medical education:

The described technique represents a definitive primary procedure for an inflamed branchial cyst. This can obviate the need for primary incision and drainage and subsequent secondary surgery.

► Please cite this paper as:

Healy C, Mahomed A. A Novel Technique for Managing Complicated Branchial Cyst. *J Minim Invasive Surg Sci.* 2012; 1(2):77-9. DOI: 10.5812/jmiss.4659

1. Introduction

Branchial cysts usually present as asymptomatic lateral cervical swelling (1). Given the propensity for progressive enlargement and the risk of infection, surgical removal is advised. Occasionally these lesions present acutely from infection with symptoms of pain or with a rapid increase in size. Conventional treatment in this case involves intravenous antibiotics with or without aspiration or an incision and drainage, followed by interval excision. Described in this paper is a technique of cystectomy for an infected giant branchial cyst. Through a limited incision the decompressed cyst is simply stripped off the inflamed abscess wall from within. An advantage is a one off therapy, averting deferred surgery with its consequences.

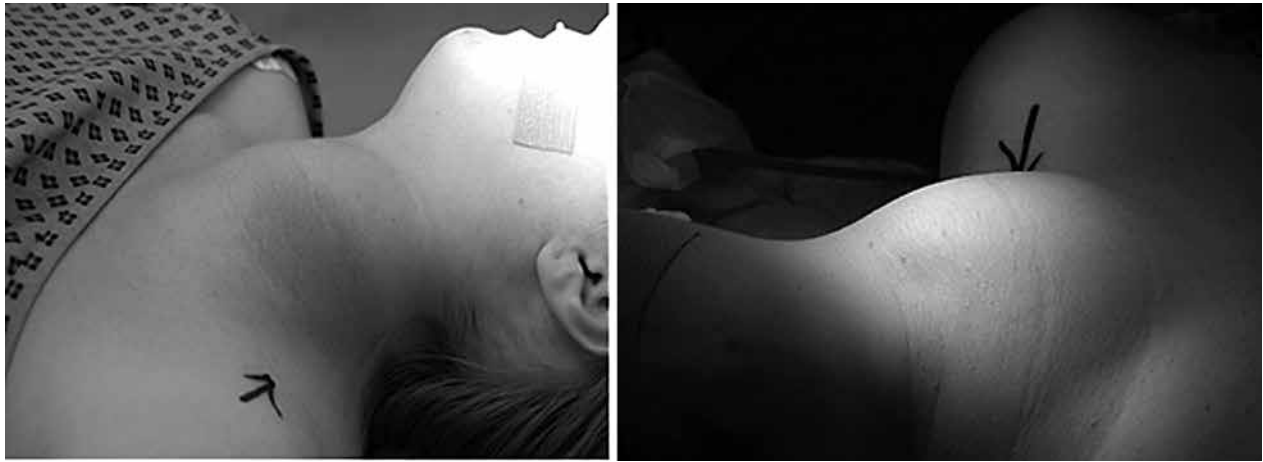
* Corresponding author: Costa Healy Department of Paediatric Surgery, Royal Alexandra Children's Hospital, Eastern Road, BN25BE Brighton, UK. Tel: +44-1273696955; Fax: +44-1273523144; E-mail: costa@doctors.org.uk

DOI: 10.5812/jmiss.4659

Copyright © 2012, Minimally Invasive Surgery Research Center and Mediterranean & Middle Eastern Endoscopic Surgery Association. This is an open-access article distributed under the terms of the Creative Commons Attribution License, which permits unrestricted use, distribution, and reproduction in any medium, provided the original work is properly cited.

2. Case Report

A 16 year old girl was seen in the Accident and Emergency (A&E) Department for a rapidly expanding mass of the left side of neck of 3 weeks duration. Examination confirmed normal vital signs and head and neck assessment revealed a tense left sided cervical swelling, extending from the inferior body of the mandible above to the clavicle below. An ultrasound scan showed a well-defined and thick walled cyst, of 4.4 cm, transverse, by 3.1 cm, antero-posterior, by 7.2 cm, craniocaudal dimension within the left side of the neck (*Figure 1*). Arrangements were made for elective excision but the patient presented in the interim to A&E with worsening symptoms and with erythema of the overlying skin suggesting cyst infection. Both CRP and WCC were elevated. A repeat ultrasound scan noted an expanding (7.5 × 7 × 5cm) unilocular cyst which appeared to split the internal jugular vein anteriorly and the carotid posteriorly, in a manner suggesting a branchial origin. The patient required drainage of the inflamed cyst as an emergency procedure, which was the primary basis for the procedure. We hoped that we could carry

Figure 1. Medial and Lateral View of Infected Branchial Cyst

Vertical extent of swelling from mandible to clavicle is apparent.

out a definitive treatment simultaneously and this was explained to the patient and her parents. The patient was taken to theatre where under a general anaesthetic with the neck extended and turned to the right, an abscess was opened and drained. A 3cm transverse skin crease incision was employed and more than 200 mL of pus evacuated. The lining of the abscess was then stripped off the capsule in a continuous piece, starting immediately under the wound, extending to its inferior and lateral limits before finally removing the superior aspect. (Figure 2) For the most part, despite the infection, separation was relatively bloodless and expeditious. Feeder vessels were controlled, as and when encountered, with bipolar diathermy. The resultant cavity was checked for haemostasis and after comprehensive washout was drained with a suction drain. The patient was sent home the following day and the drain removed 48 hours later. Microbiology of cyst's content revealed nil growth and histology confirmed a squamous epithelium lined branchial cyst with associated acute and chronic inflammation without dysplasia or malignancy. On medium term follow up no recurrence

**Figure 2.** Intra-Operative View Demonstrating Stripping of the Branchial Cyst From Within the Abscess Cavity

of the cyst has been observed.

3. Discussion

Despite an embryological origin, branchial cysts typically arise in the 3rd and 4th decades of life and are more frequently seen by adult surgeons. Though they can arise from any of the branchial remnants the majority originate from the 2nd branchial cleft and present as asymptomatic lateral neck masses (1). The failure of obliteration of the 2nd brachial cleft leads to a persistent epithelialised cyst with the potential for enlargement. The classic presentation is a mass anterior to the lower third of the sternocleidomastoid muscle. Diagnosis can be made clinically but is often confirmed radiologically by ultrasound or CT. Though the lesion is typically asymptomatic it is both cosmetically undesirable and has the potential to become infected, thus surgical excision is routinely performed as an elective procedure. This approach is appropriate when infection has not yet occurred. The surgery can be technically challenging as there is often intimate relation to neck vasculature and nerves. It has been suggested partial decompression of the cyst can aid excision (2, 3) but conversely that complete drainage creates a more difficult dissection (4). Aspiration of the inflamed cyst can also confirm the diagnosis intra-operatively when it is in doubt. As in our case culture of the inflamed cyst contents often yields no bacterial growth (5). Around one third of branchial cysts present with rapid painful enlargement due to inflammation (5). Patients with inflamed branchial cysts are conventionally managed by hospitalisation and intravenous antibiotics (4, 5). Cyst aspiration or an incision and drainage are reserved for those failing antibiotic treatment; however the management of these inflamed lesions is only demonstrated anecdotally within the literature. Generally, interval excision is undertaken following resolution of inflammation (6). Any attempt at cyst removal in the

acute setting is considered inadvisable as it purports to increase morbidity from bleeding and risks injury to cranial nerves (2). Additionally, incomplete excision with cyst recurrence is thought to be a distinct possibility. Case series of interval excisions for inflamed branchial cysts have been reported without complications or recurrence (5). All were initially treated with antibiotics though a proportion required aspiration with incision and drainage reserved for the most resistant cases. The decision to delay definitive surgery was based on prior experience with challenging operations and in particular difficulty identifying tissue planes. Our early definitive operation by contrast utilised a plane created by the inflamed cyst itself. This was assumed intraoperatively to be a stripping of the mucous lining of the cyst but transpired to be squamous epithelium on histological evaluation. There is a high recurrence rate when definitive surgery follows prior improper surgery when the diagnosis was not recognised or treated efficiently (4, 7). This probably occurs when the initial lesion has been incompletely excised and subsequent surgery misses residual epithelial remnants. This risk has hopefully been avoided in our case as the cyst was removed intact. Infection also doubles the risk of recurrence with these lesions and whether this is related to incomplete excision in these cases is not clear. An alternative option for managing inflamed cysts and one successfully employed in the presented case is comprehensive stripping of the cyst from within the abscess cavity. In this case, ablation of the lining without disrupting the reactive inflammatory capsule limits bleeding and takes care of the active cyst component preventing a recurrence. The technique, though new to this context, is not novel and has been extensively employed by gynaecologists to manage benign ovarian cysts where the ovarian parenchyma is stretched and attenuated over the cyst wall (8, 9). In this scenario ovarian reconstitution and salvage is assured by preservation of the capsule surrounding the cyst wall. However, for all these situations, it would be imperative to exclude malignancy as failure to do so could have serious repercussions for the patient. Though unlikely in the paediatric population the potential for metastatic lesions to masquerade as branchial cleft cysts exists as the metastases can undergo cystic change (1). This clearly requires alternative management and some authors have considered fine needle aspiration biopsy when this is being considered (5). The authors point out this is a significant risk within the older population. This approach to infected branchial cysts may offer several potential advantages. Firstly, its ease of performance especially when the associated surrounding inflammation makes for adverse operating conditions. Secondly, maintaining dissection within the confines of the abscess cavity reduces the risk of collateral injury to vital structures such as cranial nerves and vessels. Thirdly, enabling definitive treatment without requirement for

interval surgery, and finally, restricting the incision size and disfigurement, compared to that required for a conventional approach. Although the patient has only been followed over 6 months we are optimistic that this operation has been a definitive treatment. It has been achieved through the same incision that would have been necessary for incision and drainage of the inflamed cyst and was neither time consuming or technically challenging. Despite the advantage of the described approach, a necessary prerequisite is that the pathology be a true cyst. Evidently, pseudocysts or liquefaction within cervical glands which are clinically indistinguishable from branchial cysts, would not be amenable to this method. In this case, if a plane cannot be developed deep to the internal lining, then a simple incision and drainage with interval surgery, would be advised. Ultimately further evaluation of this technique is needed to determine whether it is definitive in all cases but when the opportunity to easily excise the cyst lining is encountered it may indeed allow a definitive treatment in the acute setting.

Acknowledgment

None declared.

Authors' Contribution

AM reported the case and CH provided the discussion. Both reviewed the finished paper.

Financial Disclosure

None declared.

Funding/Support

None declared.

References

1. Ferreiro JA, Weiland LH. Pediatric surgical pathology of the head and neck. *Semin Pediatr Surg.* 1994;**3**(3):169-81.
2. Gold BM. Second branchial cleft cyst and fistula. *AJR Am J Roentgenol.* 1980;**134**(5):1067-9.
3. Paley WG, Keddle NC. The aetiology and management of branchial cysts. *Br J Surg.* 1970;**57**(11):822-4.
4. Glosser JW, Pires CA, Feinberg SE. Branchial cleft or cervical lymphoepithelial cysts: etiology and management. *J Am Dent Assoc.* 2003;**134**(1):81-6.
5. Kadhim AL, Sheahan P, Colreavy MP, Timon CV. Pearls and pitfalls in the management of branchial cyst. *J Laryngol Otol.* 2004;**118**(12):946-50.
6. Choi SS, Zalzal GH. Branchial anomalies: a review of 52 cases. *Laryngoscope.* 1995;**105**(9 Pt 1):909-13.
7. Daoud FS. Branchial cyst: an often forgotten diagnosis. *Asian J Surg.* 2005;**28**(3):174-8.
8. Arena F, Romeo C, Castagnetti M, Scalfari G, Cimador M, Impelizzeri P, et al. Is the stripping technique a tissue-sparing procedure in large simple ovarian cysts in children? *J Pediatr Surg.* 2008;**43**(7):1353-7.
9. Muzii L, Bianchi A, Croce C, Manci N, Panici PB. Laparoscopic excision of ovarian cysts: is the stripping technique a tissue-sparing procedure? *Fertil Steril.* 2002;**77**(3):609-14.