



Hem-o-Lok Clip Is Safe in Minimally Invasive General Surgery: A Single Center Experience and Review of Data From Food and Drug Administration

Ali Aminian^{1*}, Zhamak Khorgami¹

¹ Department of General Surgery, Tehran University of Medical Sciences, Tehran, IR Iran

ARTICLE INFO

Article type:
Original Article

Article history:
Received: 12 Jul 2011
Revised: 26 Dec 2011
Accepted: 10 Jan 2012

Keywords:
Surgical Instruments
Laparoscopy
Surgical Procedures
Minimally Invasive
Cholecystectomy
Appendectomy
Splenectomy
Nephrectomy

ABSTRACT

Background: There are several methods for the ligation of structures during minimally invasive operations. The hem-o-lok clip is a nonabsorbable polymer clip with a lock engagement feature. There are few reports about its use in minimally invasive general surgical procedures. **Objectives:** In this report, we describe our experience with the hem-o-lok clip during basic, minimally invasive, general surgery procedures and the adverse events during application of the hem-o-lok.

Patients and Methods: We retrospectively reviewed all laparoscopic appendectomies (LAs), cholecystectomies (LCs), and splenectomies (LSs), performed by 6 general surgeons at a university-affiliated hospital over 4 years. Clip failure was defined as intraoperative or post-operative bleeding due to clip malfunction that necessitated placement of another clip, conversion to an open procedure, or postoperative re-exploration. Leakage from the cystic duct and appendiceal stump was also considered clip failure. A search of the US Food and Drug Administration Manufacturer and User Facility Device Experience (MAUDE) database using the appropriate keywords was performed on July 7, 2011. This online resource contains reports of adverse events involving medical devices.

Results: Over a 4-year period, 856 laparoscopic operations, comprising 770 LC, 55 LS, and 31 LA, were performed. We did not observe any incidence of clip failure. There were 22 reports of hem-o-lok clip failure in the MAUDA database. Eighty-two percent (n = 18) of clip failures were reported during laparoscopic nephrectomy. There was no report of failure after LA. There were 2 reported clip failures after LC (with bile leakage) and 1 after LS (tearing of splenic vessels with intraoperative bleeding). There was also a report of migration of the hem-o-lok clip into the common bile duct, which occurred 4 years after a complicated LC.

Conclusions: Hem-o-lok clips that are properly applied during basic laparoscopic procedures are a secure option for the ligation of the structures. Surgeons must be educated regarding the proper application technique.

► Implication for health policy/practice/research/medical education:

There are several methods for the ligation of structures during minimally invasive operations. The hem-o-lok clip is a polymer clip with a lock engagement feature. According to this study, properly applied hem-o-lok clips during basic laparoscopic procedures are a safe option for ligation of structures. We present this study to educate the surgeons about the proper use of hem-o-lok clips during minimally invasive general surgery.

► Please cite this paper as:

Aminian A, Khorgami Z. Hem-o-Lok Clip is Safe in Minimally Invasive General Surgery: A Single Center Experience and Review of Data From Food and Drug Administration. *J Minim Invasive Surg Sci.* 2012;1(2): 52-7. DOI: 10.5812/jmiss.1885

* Corresponding author: Ali Aminian, Department of General Surgery, Imam Khomeini Hospital, Keshavarz Blv, Tehran, IR Iran. Tel: +98-2166581657, Fax: +98-2166581657, E-mail: aaminian@tums.ac.ir

DOI: 10.5812/jmiss.1885

Copyright © 2012, Minimally Invasive Surgery Research Center and Mediterranean & Middle Eastern Endoscopic Surgery Association. This is an open-access article distributed under the terms of the Creative Commons Attribution License, which permits unrestricted use, distribution, and reproduction in any medium, provided the original work is properly cited.

1. Background

There are several methods of ligating structures during laparoscopic operations. Several studies have examined the efficacy, safety, and cost of various devices in different situations. Each technique has potential

drawbacks. Application of endoloops requires dexterity and training. Endoscopic staplers are expensive instruments. Titanium clips can slip from their primary position (1). The hem-o-lok clip (Weck Closure Systems, Research Triangle Park, NC) (Figure 1) was introduced in 1999. This nonabsorbable polymer clip has a lock engagement feature, as well as teeth in the jaws that provide good security. In addition, recent experimental studies have tested the ability of the hem-o-lok to withstand supraphysiological pressures in comparison with other devices (1, 2). This clip has gained popularity among laparoscopic urologists, primarily for the ligation of vessels of the renal hilum during minimally invasive nephrectomy, effecting appropriate results (1, 3). We and many others have also adopted the hem-o-lok for a variety of laparoscopic procedures in recent years. However, few reports have examined its use in laparoscopic general surgical procedures.

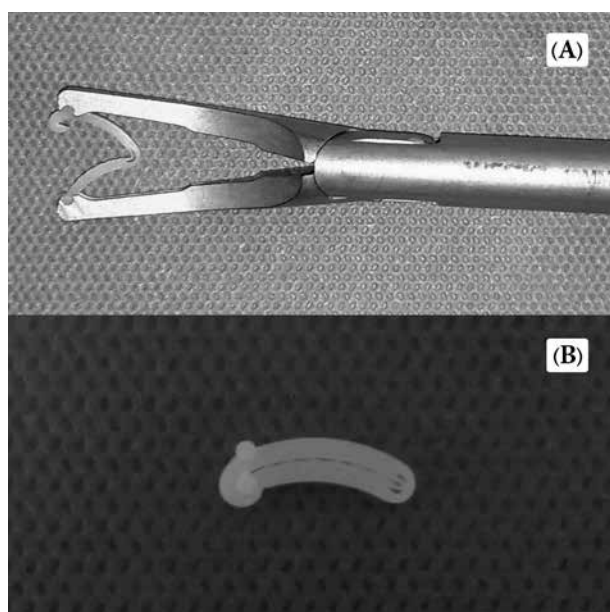


Figure 1. A) Hem-o-Lok Clip in Applicator; B) Locked Clip With Uniform Teeth

2. Objectives

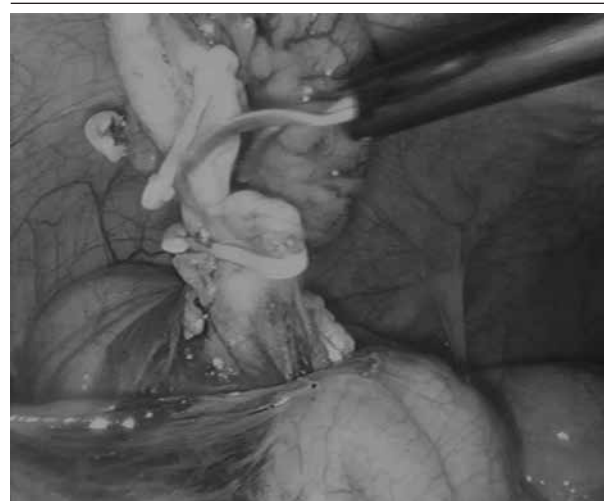
In this report, we describe our experience with the hem-o-lok clip during basic, minimally invasive, general surgery procedures and report the adverse events during application of the hem-o-lok in the Food and Drug Administration database of medical devices.

3. Patients and Methods

The hem-o-lok has been used routinely in our operating room at a university-affiliated tertiary hospital since 2006. We retrospectively reviewed all laparoscopic appendectomies, cholecystectomies, and splenectomies that were performed by 6 surgeons over four years. In a laparoscopic appendectomy (LA) for the closure of the

base of an appendix, 1 hem-o-lok clip is applied on the patient side, and 1 clip is applied on the specimen side (Figure 2). Occasionally, ligation of the mesoappendix is also performed with a hem-o-lok (4). During a laparoscopic cholecystectomy (LC), 1 or 2 hem-o-lok clips are placed on the proximal part of the cystic duct, and 1 is placed on the distal section (Figure 3). In most cases, ligation of the cystic artery is also performed with application of a hem-o-lok clip. During a laparoscopic splenectomy (LS), after circumferential dissection of the splenic artery and vein, 2 hem-o-lok clips are placed on the patient side of each vessel, and 1 is placed on the splenic side (Figure 4).

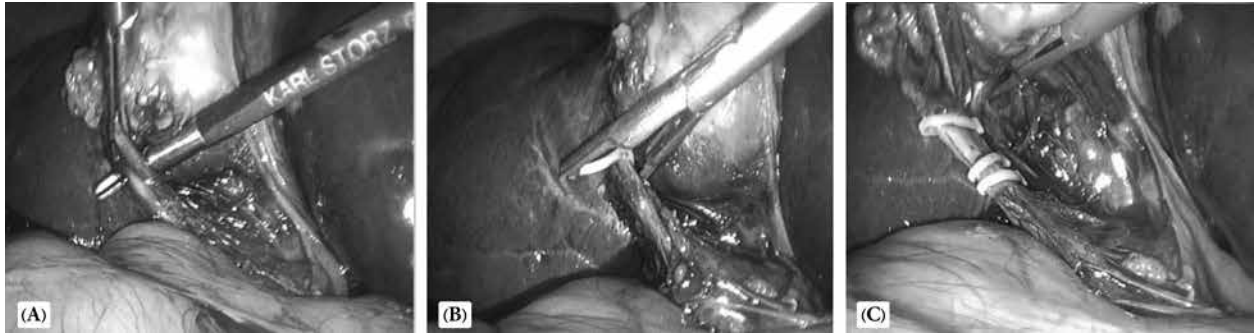
Figure 2. Laparoscopic Appendectomy



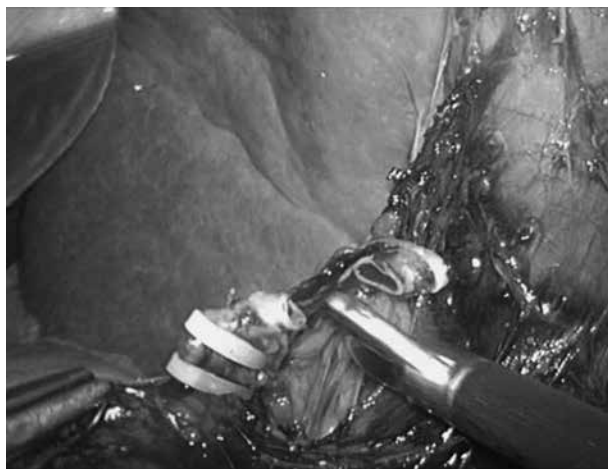One hem-o-lok clip is applied on the appendiceal stump and one clip on the specimen side.

Clip failure was defined as intraoperative or postoperative bleeding due to clip malfunction that necessitated placement of another clip, conversion to an open procedure, or postoperative re-exploration. Leakage from the cystic duct after LC and appendiceal stump after LA was also considered clip failure. A search of the US Food and Drug Administration (FDA) Manufacturer and User Facility Device Experience (MAUDE) database was performed on July 7, 2011. This online resource contains reports of adverse events involving medical devices and is updated quarterly. MAUDE contains all voluntary reports since June 1993, user facility reports since 1993, distributor reports since 1993, and manufacturer reports since August 1996 (1).

We performed multiple searches using the following keywords, alone or in combination: Weck, hem-o-lok, clip, appendectomy, cholecystectomy, splenectomy, and laparoscopy. The results of these searches were reviewed, and only those involving the hem-o-lok clip in minimally invasive general surgery procedures were included. All text fields were reviewed to determine the nature of the incidents and manufacturer responses.

Figure 3. Laparoscopic Cholecystectomy

A) After circumferential dissection of cystic duct; B) visualization of the curved tip of the clip around and beyond it; C) one or two hem-o-lok clips are placed on the proximal part of cystic duct and one is placed on the distal part.

Figure 4. Laparoscopic Splenectomy

Two hem-o-lok clips are placed on the patient side of splenic artery and one is placed on the splenic side. Note the placement of clip at 90 degree to the artery and appropriate visual stump.

4. Results

Between July 2006 and June 2009, 856 laparoscopic operations, comprising 770 LC, 55 LS, and 31 LA, were performed. The number of clips that were placed on the patient side of the splenic artery and vein was most often 2. The number of clips that were used for the ligation of the cystic duct and artery, the appendiceal base and its mesentery, and the specimen side of splenic vessels was most often 1, occasionally 2. We did not observe any incidence of clip failure. In the MAUDA database, we identified 22 reports of hem-o-lok clip failure. Eighteen cases (82%) of clip failure were reported during minimally invasive nephrectomy. There was no report of failure after LA. There were 2 clip failures after LC (with bile leakage) and 1 after LS (tearing of splenic vessels with intraoperative bleeding). There was also a reported case of migration of the clip into the common bile duct (CBD). This patient underwent LC, which was converted to an open procedure due to iatrogenic CBD injury. The surgeon used only

1 clip for ligation of the cystic artery. After 4 years, the patient underwent endoscopic removal of a CBD stone, and a closed hem-o-lok clip was found in the center of the stone.

5. Discussion

Released in 1999, the hem-o-lok clip has been a useful alternative to titanium clips, endoloops, and endoscopic staplers (1). There are 4 sizes of hem-o-lok clips and applicators (M, ML, L, and XL), from 2 mm to 16 mm, for ligation of structures during minimally invasive surgery. Clips ligate up to 10 mm of tissue through a 5-mm trocar and up to 16 mm through a 10-mm trocar. This non-absorbable polymer locking clip is inert, non-conductive, and compatible with CT scan and MRI. The lock engagement feature and the presence of teeth in the jaws provide good security. Loading of the applicator with the clip is easy, and a flexible mechanism virtually prevents clips from falling out of the applicator. There are several reports about the safety of hem-o-lok clips in minimally invasive operations. Endourologists have used these clips widely during laparoscopic nephrectomy for more than a decade (1-3, 5, 6). We previously presented the safety and feasibility of the hem-o-lok clip for ligation of the appendiceal base and mesentery during LA. Other surgeons have also shown a similar result with a single hem-o-lok on the appendiceal stump (7, 8). There are published reports in favor of its application during minimally invasive cholecystectomy (1), prostatectomy (9), hysterectomy (10), and lung lobectomy (11). In this study, we have presented the results of the application of hem-o-lok clips during minimally invasive cholecystectomy, appendectomy, and splenectomy in 856 patients. We did not observe any cases of clip failure.

The MAUDE database is a reporting system mandated by the FDA for the surveillance of medical devices. It includes reports of adverse events involving medical devices that occur after device approval. MAUDE has been transformed into a searchable online database (<http://www.accessdata.fda.gov/scripts/cdrh/cfdocs/cfMAUDE/search.CFM>) (12). Recently, many reviews of MAUDE data have been published (1,

6, 13), attempting to summarize adverse events in the database. For the clinician who is considering the use of a new medical device, the MAUDE database is useful for searching for complications that have not been reported in the medical literature (13). Overall, relatively few incidents of clip failure during minimally invasive general surgery have been reported in the MAUDE database. In the MAUDE database, we found 3 reports of clip failure after LC and 1 report during LS. However, these reports to the FDA are voluntary, and it is possible that a significant number of events are never reported (1). Additionally, attempts to quantify the occurrence of adverse events as a risk percentage are limited, because the absolute number of procedures performed by any given device is not tracked by the FDA and is unavailable in the MAUDE database (13). Accordingly, the FDA website states that "MAUDE data are not intended to be used either to evaluate rates of adverse events or to compare adverse event occurrence rates across devices" (14).

Meng *et al.* published 2 reviews using the MAUDE database on failures of hem-o-lok clips and endoscopic staplers (15). These series focused primarily on urological procedures. There were 9 reports of hilar bleeding with application of hem-o-lok clips during minimally invasive nephrectomy. In 1 case, hilar bleeding was controlled by the placement of titanium clips on the arterial stump proximal to the 2 hem-o-lok clips. In the other 8 cases, immediate open conversion ($n = 1$), delayed open surgical exploration ($n = 5$), and death ($n = 2$) occurred. No clear cause of bleeding was identified, and multiple clips were applied intraoperatively with apparent vascular control. True catastrophic events have been reported with the hem-o-lok clip, even with 2 clips placed on the patient side. One autopsy report questioned whether the artery proximal to the clips had ruptured. The authors concluded that all forms of vascular control are liable to fail and may result in bleeding, morbidity, and death. A significantly larger number of problems have been documented in the MAUDE database with the linear stapler in comparison with hem-o-lok clips, which are likely to be related to the popularity and greater use of linear staplers. However, the delayed presentation of hem-o-lok clip failure is particularly worrisome during nephrectomy and does not appear to be predictable. In contrast, all bleeding that is associated with the failure of staplers was noted during the application, firing, or removal of the device, and bleeding occurred immediately, providing an opportunity to correct the situation immediately (1, 15).

In April 2006, the manufacturer of hem-o-lok clips, Teleflex Medical, released a contraindication for its use in ligating the renal artery during laparoscopic nephrectomy in living donor patients after receiving 15 medical device reports of 12 injuries and 3 deaths, all of which occurred between November 2001 and March 2005 (16). All reports were associated with the use of hem-o-lok clips for ligation of the renal artery during laparoscopic living-donor nephrectomies. Since the contraindication was issued in

2006, there have been 3 additional kidney donor deaths, all associated with the contraindicated use (17).

Although there are several articles that appear to endorse the continued use of hem-o-lok clips for ligating the renal artery during laparoscopic living-donor nephrectomies (1-3, 5, 6), the FDA has stressed that the clips are contraindicated for this use due to the risk of life-threatening bleeding. In January 2011, the American Society of Transplant Surgeons (ASTS) issued separate safety notifications reinforcing this contraindication (17).

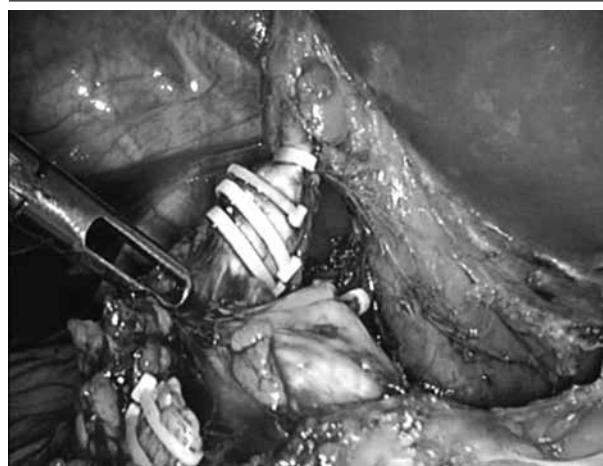
There are several important principles in the application of hem-o-lok clips (*Sidebar*). Three previous reports

Sidebar. Important Principles of Hem-O-Lok Clip Application^a

1. Complete circumferential dissection of the structure (*Figure 3A*)
2. Use the appropriate size of clip (*Figure 5*)
3. Visualization of the curved tip of the clip around and beyond the structure (*Figure 3B*)
4. Feeling of the tactile snap when the clip latched
5. Maintenance of a visual stump below the most proximal clip (*Figures 4 and 5*)
6. No cross-clipping
7. Placement of clip at 90 degree to the structure (*Figures 2, 3, and 4*)
8. Not squeezing handles of clip applicator too hard (compared with the application of metal clips)
9. Careful removal of the applicator after application of clip (the tips of applicator are sharp and can cause a laceration of nearby vessels)
10. Inspection the ligation site after application to ensure security and proper closure
11. Partial division of vessels initially to confirm hemostasis before complete transection
12. Minimum of two clips placed on the patient side of the large vessel (i.e., splenic hilar vessels) (*Figure 4 and 5*)

^a Modified table from Ponsky *et al.* (3)

Figure 5. Laparoscopic Splenectomy



Minimum of two clips is placed on the patient side of the large vessels such as splenic vein. Note that the size of third clip from below is not appropriate. The transected splenic artery is also visualized in the left lower corner.

showed that with consideration of these principles, the failure rates of hem-o-lok clips are near zero (1-5). The manufacturer recommends that more than 1 clip be used to ligate the renal artery in procedures other than laparoscopic donor nephrectomies (which has been considered a contraindication). Application of more than 1 clip to all other tissues should be left to the surgeon's judgment (16).

We have good experience with applying 2 clips for the ligation of large vessels, such as splenic hilar vessels, and 1 clip for small vessels, such as cystic and appendicular arteries. Based on our experience, 2 clip is sufficient for ligating the cystic duct and the base of the appendix. The use of clips that have the appropriate size is important for proper ligation. A clip that is too large may not remain on the tissue due to the relatively larger gap between the jaws of the locked clip (*Figure 1B*). This is more important in ligating veins due to the risk of clip slippage from a thin vein. Conversely, too much tissue within a clip places greater pressure on the jaws and may increase the likelihood of failure of the locking system (1).

There is an interesting case of postcholecystectomy hem-o-lok clip migration into the CBD in the MAUDE database. Migration of the clip into the CBD and the resulting stone formation is a rare but well-recognized complication of cholecystectomy. Recently, Chong et al. published a review of 69 publications reporting 80 such cases. Metal clips were used in all cases except for 2, for which absorbable clips were used. The median time from cholecystectomy to clinical presentation of the migrated clip was 26 months (range, 11 days to 20 years). Most of the patients presented with typical symptoms of CBD stone, and endoscopic removal (ERCP) was successful in most cases (18). There is no reported case of hem-o-lok clip migration after cholecystectomy in the medical literature. However, there are several reports of migration of the hem-o-lok clip during radical prostatectomy into the rectum (19) and urinary bladder, with subsequent bladder stone formation (20-23).

We present this study to educate the surgeons about the proper use of hem-o-lok clips during minimally invasive general surgery. Properly applied hem-o-lok clips during basic laparoscopic procedures are a safe option for ligation of the structures. Surgeons must be educated regarding its proper application. Operating surgeons should also be familiar with other methods of ligation, such as energy sources, staplers, and knot tying, to be applied in the event of failure of hem-o-lok clips.

Acknowledgements

None declared.

Authors' Contribution

AA performed the study and prepared the manuscript. ZK reviewed the manuscript.

Financial Disclosure

None declared.

Funding/Support

None declared.

References

- Meng MV. Reported failures of the polymer self-locking (Hem-o-lok) clip: review of data from the Food and Drug Administration. *J Endourol.* 2006;**20**(12):1054-7.
- Jellison FC, Baldwin DD, Berger KA, Maynes LJ, Desai PJ. Comparison of nonabsorbable polymer ligating and standard titanium clips with and without a vascular cuff. *J Endourol.* 2005;**19**(7):889-93.
- Ponsky L, Cherullo E, Moinzadeh A, Desai M, Kaouk J, Haber GP, et al. The Hem-o-lok clip is safe for laparoscopic nephrectomy: a multi-institutional review. *Urology.* 2008;**71**(4):593-6.
- Aminian A, Karimian F, Toolabi K, Mirsharifi R. Technical modifications in laparoscopic appendectomy. *World J Lap Surg.* 2011;**4**(1):1-4.
- Simforoosh N, Aminsharifi A, Zand S, Javaherforooshzadeh A. How to improve the safety of polymer clips for vascular control during laparoscopic donor nephrectomy. *J Endourol.* 2007;**21**(11):1319-22.
- Hsi RS, Ojogho ON, Baldwin DD. Analysis of techniques to secure the renal hilum during laparoscopic donor nephrectomy: review of the FDA database. *Urology.* 2009;**74**(1):142-7.
- Koluh A, Delibegovic S, Hasukic S, Valjan V, Latic F. Laparoscopic appendectomy in the treatment of acute appendicitis. *Med Arh.* 2010;**64**(3):147-50.
- Partecke LI, Kessler W, von Bernstorff W, Diedrich S, Heidecke CD, Patrzyk M. Laparoscopic appendectomy using a single polymeric clip to close the appendicular stump. *Langenbecks Arch Surg.* 2010;**395**(8):1077-82.
- Yi JS, Kwak C, Kim HH, Ku JH. Surgical clip-related complications after radical prostatectomy. *Korean J Urol.* 2010;**51**(10):683-7.
- Feuer G, Hernandez P, Barker J. Surgical technique enhances the efficiency of robotic hysterectomy. *Int J Med Robot.* 2011;**7**(1):1-6.
- Bignon H, Buela E, Martinez-Ferro M. Which is the best vessel-sealing method for pediatric thoracoscopic lobectomy? *J Laparoendosc Adv Surg Tech A.* 2010;**20**(4):395-8.
- U. S. Food and Drug Administration. MAUDE - Manufacturer and User Facility Device Experience. 2011 [updated 30 Dec 2011]; Available from: <http://www.accessdata.fda.gov/scripts/cdrh/cfdocs/cfMAUDE/search.CFM>.
- Gurtcheff SE. Introduction to the MAUDE database. *Clin Obstet Gynecol.* 2008;**51**(1):120-3.
- U. S. Food and Drug Administration. Manufacturer and User Facility Device Experience Database - (MAUDE). 2011; Available from: <http://www.fda.gov/MedicalDevices/DeviceRegulationandGuidance/PostmarketRequirements/ReportingAdverseEvents/ucm127891.htm>.
- Deng DY, Meng MV, Nguyen HT, Bellman GC, Stoller ML. Laparoscopic linear cutting stapler failure. *Urology.* 2002;**60**(3):415-9; discussion 9-20.
- Teleflex Medical. Letter. Contraindication for Use of Hem-o-lok Ligating Clips in Laparoscopic Donor Nephrectomy. 2006; Available from: http://www.swissmedic.ch/recalllists_dl/01155/Vk_20060608_06-e1.pdf.
- U. S. Food and Drug Administration. FDA and HRSA Joint Safety Communication: Weck Hem-o-Lok Ligating Clips Contraindicated for Ligation of Renal Artery During Laparoscopic Living-Donor Nephrectomy. 2011; Available from: <http://www.fda.gov/MedicalDevices/Safety/AlertsandNotices/ucm253237.htm>.
- Chong VH, Chong CF. Biliary complications secondary to post-cholecystectomy clip migration: a review of 69 cases. *J Gastrointest Surg.* 2010;**14**(4):688-96.
- Wu SD, Rios RR, Meeks JJ, Nadler RB. Rectal Hem-o-Lok clip migra-

- tion after robot-assisted laparoscopic radical prostatectomy. *Can J Urol*. 2009;**16**(6):4939-40.
20. Moser RL, Narepalem N. Erosion of Hem-o-Lok clips at the bladder neck after robot-assisted radical prostatectomy. *J Endourol*. 2009;**23**(6):949-51.
 21. Tunnard GJ, Biyani CS. An unusual complication of a Hem-o-Lok clip following laparoscopic radical prostatectomy. *J Laparosc Adv Surg Tech A*. 2009;**19**(5):649-51.
 22. Tugcu V, Polat H, Ozbay B, Eren GA, Tasci AI. Stone formation from intravesical Hem-o-lok clip migration after laparoscopic radical prostatectomy. *J Endourol*. 2009;**23**(7):1111-3.
 23. Mora ER, Gali OB, Garin JA, Arango O. Intravesical migration and spontaneous expulsion of a Hem-o-lok polymer ligating clip after laparoscopic radical prostatectomy. *Urology*. 2010;**75**(6):1317.