

# Laparoscopic Repair of Duodenal Perforation by “Hanging Method” -Technique and Benefits

Annu Babu,<sup>1\*</sup> Ankit Raikhy,<sup>1</sup> Homagni Ghosh,<sup>2</sup> Partha Sarathi Nayak,<sup>2</sup> Abhishek Bhartia,<sup>3</sup> and V K

Bhartia<sup>4</sup>

<sup>1</sup>Senior Resident, Department of Minimal Access and Bariatric Surgery, CMRI, Kolkata, India

<sup>2</sup>Junior Resident, Department of Minimal Access and Bariatric Surgery, CMRI, Kolkata, India

<sup>3</sup>Consultant, Department of Minimal Access and Bariatric Surgery, CMRI, Kolkata, India

<sup>4</sup>Prof and Head of Department, Department of Minimal Access and Bariatric Surgery, CMRI, Kolkata, India

\*Corresponding author: Annu Babu, Room no -4, Upper Dake, CMRI, 7/2, Diamond Harbour Road, Kolkata, West Bengal, India. Tel: +91-8130016696, E-mail: drannubabu@yahoo.co.in

Received 2016 December 05; Revised 2017 January 10; Accepted 2017 January 28.

## Abstract

**Background:** Laparoscopic repair of duodenal perforation using the omental patch is one of the traditional techniques, which gives better postoperative recovery in patients with little chances of abdominal wound infection. This article is about the technique used for the laparoscopic repair of the duodenal perforation by Grahams patch with a twist in the conventional technique.

**Methods:** In Hanging method of duodenal repair first, an intra-corporeal suture is taken at the upper margin of perforation and both end of the thread is taken out of anterior abdominal wall and duodenum is pulled up. Now under vision the next two parallel sutures are passed, thus avoiding the posterior duodenal wall incorporation. Finally omentum flap is used for the closure of perforation.

**Conclusions:** The laparoscopic closure of the duodenal perforation by “Hanging Method” is an appropriate Laparoscopic technique, as “hanging” the anterior wall of duodenum gives us better vision of the posterior wall of duodenum, while taking the suture through anterior duodenal wall. Further since the gall bladder is retracted there is an easy available working space for intracorporeal suturing.

**Keywords:** Duodenal Ulcer, Hanging Method, Laparoscopic, Omental Patch, Suture

## 1. Background

The peptic ulcer disease (PUD) affects 4 million people worldwide (1). The incidence of PUD has been 1.5% - 3% (2). Although 10% - 20% of the patients with history of PUD will complicate, out of this 2% - 14% patient will have perforation peritonitis (3-5). Patients with PUD perforation carries high risk of mortality and morbidity (6). The life time incidence of perforation in peptic ulcer disease is 5% (7). The mortality of perforated peptic ulcer is 1.3% - 20% (8-10). The day 3 mortality rate is 20% and day 90 mortality rate is 30% (11). The laparoscopic repair of the duodenal perforation was started in 1990 by Mouret et al. Studies have suggested the better outcome of laparoscopic surgery for the duodenal perforation, then open surgeries in term of pain, postoperative recovery and abdominal wound complications (12). Laparoscopic approach provides better peritoneal lavage and better visualization of the peritoneal cavity (13). Laparoscopic approach is limited to the patients with stable vitals, as it takes a little longer operative time than open procedure (13). Simple closure with omental patch has been always the favored method for the emer-

gency procedures. The laparoscopic duodenal perforation repair give benefit of less post-operative pain, early return to normal work and less wound infection but at the same time laparoscopic procedure needs the expertise training, which limits its wide acceptibility (14). This article is about the technique used for the laparoscopic repair of the duodenal perforation by Grahams patch with a twist in the conventional technique.

## 2. Methods

The conventional laparoscopic duodenal perforation repair included the five laparoscopic port insertion supraumbilical 10 mm (camera port), left midclavicular 10 mm (right hand working port), right midclavicular subcostal 5 mm (left hand working port), subxiphoid 5 mm (left lobe liver retraction), left anterior axillary line 5 mm (for stomach retraction). In our method we used one umbilical 10 mm (camera port), and three 5mm port, one in right hypocondrium (left hand working port), another in left hypocondrium (right hand working port) and

third one in right anterior axillary line (for gall bladder retraction).

After insertion of the ports peritoneal lavage is started with normal saline till the affluent is clear. Perforation site is visualized and flakes around the perforation is cleared. Gall bladder is retracted using right anterior axillary line port with a grasper. Vicryl 2-0 thread is used for the perforation closure and is introduced via 10 mm camera port. An intra corporeal suture is taken at the upper margin of perforation (Figure 1) and needle end of thread is cut and needle is parked in the anterior abdominal wall. Now using the Berci transfacial suture passer both end of the thread is taken out of anterior abdominal wall (Figure 2) and little tension is given so that the anterior wall of the duodenum is pulled up (Hanging Method) and the perforation is visualized (Figure 3). Posterior wall of the duodenum can be easily observed after lifting the duodenum up. Under the vision the next two parallel sutures are passed. This suture can be taken under vision, thus avoiding the posterior duodenal wall incorporation. The free omentum available is used for the closure over the perforation. If free omentum is not available due to adhesions and inflammatory changes then using the harmonic shear the attached omentum is divided from one side so that vascularity is preserved on the other side and a flap of omental patch is created. This omental patch is applied in between the stay sutures (Figure 4). The hanging sutures are released and utilized to tie the upper margin of omental patch. Drain was placed. We have performed 10 cases by this method and detail statistical data of all the patients is given in Table 1.

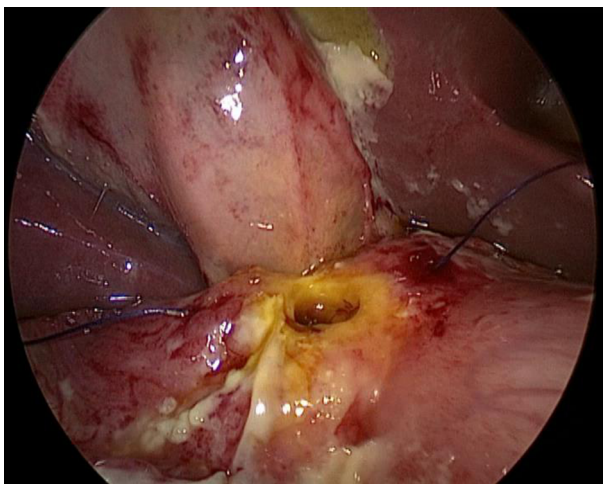


Figure 1. Passing the Intracorporeal Suture with Vicryl 2-0

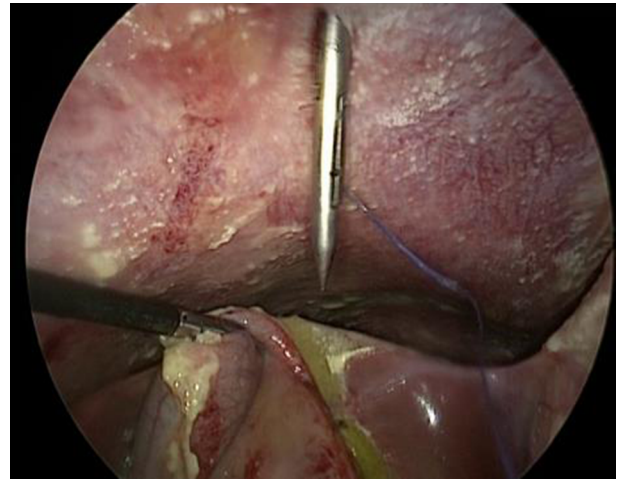


Figure 2. Pulling Out the Suture Vicryl 2-0 Through the Abdomen Wall Using Berci transfacial Suture Passer

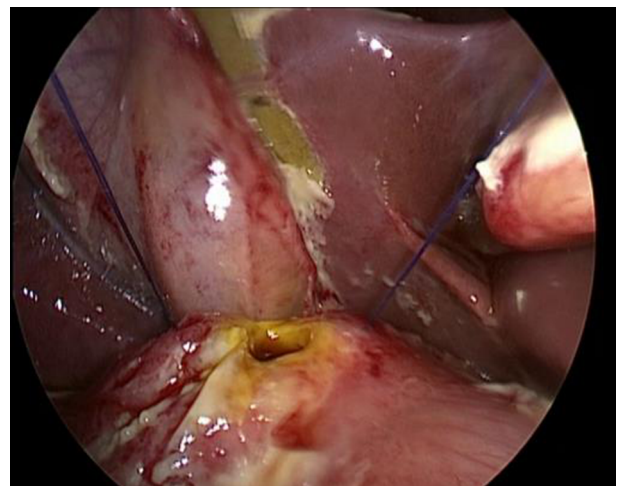


Figure 3. Pulling the Both Sides of Passed Suture Vicryl 2-0 So That Duodenum Hangs Up in the Air

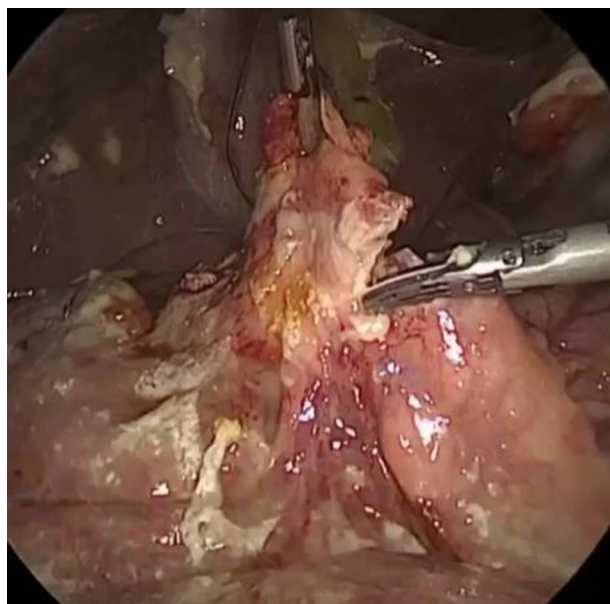
### 3. Results

In all cases performed in our institute we used this technique and mean operating time was approximately 70 minutes. Mean age of our patients was 47.1 years. Nine patients were male with one female patient and there mean body mass index was 26.2 kg/m<sup>2</sup>. Harmonic shear was used in 5 cases to get free omental flap, because of the high contamination, omentum was adherent to the surrounding structures. Use of harmonic added to the cost of operation but it saved time from extra dissection needed to free the omentum along with undue bleeding. The size of perforation was estimated and divided into 5 mm, 10 mm, 15 mm

**Table 1.** Statistical Data of all the Patients Managed by Laparoscopic Duodenal Perforation Repair by Hanging Method

SR. No.	Age, y	Sex	BMI, Kg/m <sup>2</sup>	ASA	Day of Presentation Since Pain Abdomen	Perf. Size, mm	Harm-Monic Used, Y/N	Contamination, Y/N	Diet Start Day	Operative Time, min	Complication	Hospital Stay, day
1.	29	M	21	1	2	5	Y	Y	3	75	NIL	6
2.	40	M	26	1	1	10	N	Y	4	75	NIL	7
3.	38	F	22	2	3	10	Y	Y	3	70	NIL	6
4.	35	M	29	1	1	10	N	Y	4	60	NIL	7
5.	55	M	32	2	2	15	Y	Y	4	90	Pelvic collection	12
6.	43	M	24	1	1	5	N	N	2	55	NIL	4
7.	56	M	30	1	1	10	N	N	3	60	NIL	6
8.	44	M	27	1	2	5	Y	Y	2	70	NIL	4
9.	70	M	22	3	2	10	Y	Y	4	70	NIL	7
10	61	M	29	1	1	5	N	N	3	70	NIL	6
<b>TOTAL MN/MD</b>	MN-47.1	M-9F-1	MN-26.2	MD-1 (1:3)	MN-1.6	MN-8.5			MN-2.2	MN-69.5		MN-6.5

Abbreviations: MD, Median; MN, Mean.

**Figure 4.** Creating the Omental Flap Using Harmonic

and the mean perforation size was 8.5 mm. Larger perforation was associated with a more contamination and inflammation around the perforation. We performed one case with perforation size of 15 mm, oral feeding started after 4 days. Postoperatively patient developed some pelvic collection which was dealt with single time aspiration. Routine analgesics were used in the post-operative period. Patient was made to ambulate on day 2 of the surgery. Patients were started an oral diet on day 2 to 4 (mean 2.2 days) in the postoperative period. The mean hospital stay was

6.5 days. There was no port site wound infection. Post-operative endoscopy done after 8 weeks follow up was normal.

#### 4. Discussion

Peptic ulcer perforation is a serious problem in the elderly persons and causes major mortality (1, 2). The non-operative treatment for the duodenal perforation is also effective. But in the clinical situation with limited resources the monitoring is quite difficult. There is relative disagreement to the non-operative treatment of duodenal perforation vs. simple operative closure. The advent of proton pump inhibitors have reduced the need for surgical intervention in duodenal ulcer disease. Still after so many years, the rate of complication remains the same. The pharmacological approach has played role in the treatment of *Helicobacter pylori* induced recurrence.

The need of surgical intervention is always associated with some morbidity and mortality. The laparoscopic surgery for duodenal perforation was started in the year 1990 (12). A systemic review of three randomized control study in 315 patient comparing the open and laparoscopic duodenal perforation repair suggested that operative time for the laparoscopic duodenal perforation repair is less than the open as contrary to the previous studies but this study failed to suggest difference in the abdominal septic complications, pulmonary complications, morbidity, mortality, and reoperation rate (15). A systemic review of 56 studies could not suggest the better technique between the two open and laparoscopy approach (16). The size of perforation is a factor for conversion to the open procedure, the rate of conversion is 12.4% in some study (17). The

conversion to open procedure is more when the perforation size is 9 mm or more (18, 19). The leakage rate and operative time was also more in laparoscopy group in some studies (19). There was less need of postoperative analgesia and better mobilization of the patient in postoperative period in laparoscopic approach and the cost of surgery of open and laparoscopy was almost similar. Recent trials have shown that the patient with Boey score 3 and age more than 70 years and perforation duration more than 24 hours should undergo open surgery (20, 21). The laparoscopic duodenal perforation surgery requires more expertise in laparoscopic skill but at the some medical centre it is also done by trainee doctors and has produced desired results (22, 23).

Our technique aims to make this procedure easy and safe. While doing the laparoscopic intracorporeal suturing there is always problem of depth perception, loss of 3 dimensional vision and small working space during passing the needle through the tissue (24, 25). This technique of “hanging” the anterior wall of duodenum gives us better vision of the posterior wall of duodenum, while taking the suture through anterior duodenal wall. Further, ince the gall bladder is retracted there is an easy available working space for intracorporeal suturing. This procedure can actually reduce the operative time as the working space for the intracorporeal suturing is large and the duodenal wall is in proper traction and can be easily manipulated.

#### 4.1. Conclusion

The laparoscopic closure of the duodenal perforation by “Hanging Method” is an appropriate Laparoscopic technique, as “hanging” the anterior wall of duodenum gives us better vision of the posterior wall of duodenum, while taking the suture through anterior duodenal wall. Further since the gall bladder is retracted there is an easy available working space for intracorporeal suturing. In addition it give all benefits of minimal access surgery like less analgesic requirement in post-operative period, shorter hospital stay and also less chances of the abdominal wound infection.

#### 4.2. Limitation

This study lacks randomization and comparison, but here it illustrates that how we have progressed from case one to ten in laparoscopic duodenal perforation repair. The further study is needed before we reach any conclusion of the benefits of this procedure over conventional technique.

## Footnotes

**Authors’ Contribution:** Annu Babu and Ankit Raikhy made substantial contributions to conception and design and revision of manuscript. Homagni Ghosh and Partha Sarathi Nayak have been involved in acquisition of data and drafting the manuscript. Annu Babu and V K Bhartia made substantial contribution to the review. All authors read and approved the final manuscript.

**Conflict of Interest:** All authors declared no conflict of interest.

**Consent:** Written and informed consent was obtained from the patient for publication of this Case report and any accompanying images.

## References

1. Zelickson MS, Bronder CM, Johnson BL, Camunas JA, Smith DE, Rawlinson D, et al. Helicobacter pylori is not the predominant etiology for peptic ulcers requiring operation. *Am Surg.* 2011;77(8):1054-60. [PubMed: 21944523].
2. Zittel TT, Jehle EC, Becker HD. Surgical management of peptic ulcer disease today-indication, technique and outcome. *Langenbecks Arch Surg.* 2000;385(2):84-96. doi: 10.1007/s004230050250. [PubMed: 10796046].
3. Sung JJ, Kuipers EJ, El-Serag HB. Systematic review: the global incidence and prevalence of peptic ulcer disease. *Aliment Pharmacol Ther.* 2009;29(9):938-46. doi: 10.1111/j.1365-2036.2009.03960.x. [PubMed: 19220208].
4. Bertleff MJ, Lange JF. Perforated peptic ulcer disease: a review of history and treatment. *Dig Surg.* 2010;27(3):161-9. doi: 10.1159/000264653. [PubMed: 20571260].
5. Lau JY, Sung J, Hill C, Henderson C, Howden CW, Metz DC. Systematic review of the epidemiology of complicated peptic ulcer disease: incidence, recurrence, risk factors and mortality. *Digestion.* 2011;84(2):102-13. doi: 10.1159/000323958. [PubMed: 21494041].
6. Bas G, Eryilmaz R, Okan I, Sahin M. Risk factors of morbidity and mortality in patients with perforated peptic ulcer. *Acta Chir Belg.* 2008;108(4):424-7. doi: 10.1080/00015458.2008.11680254. [PubMed: 18807594].
7. Vaira D, Menegatti M, Miglioli M. What is the role of Helicobacter pylori in complicated ulcer disease? *Gastroenterology.* 1997;113(6 Suppl):S78-84. doi: 10.1016/S0016-5085(97)80017-0. [PubMed: 9394765].
8. Boey J, Choi SK, Poon A, Alagaratnam TT. Risk stratification in perforated duodenal ulcers. A prospective validation of predictive factors. *Ann Surg.* 1987;205(1):22-6. doi: 10.1097/00000658-198701000-00005. [PubMed: 3800459].
9. Hermansson M, Stael von Holstein C, Zilling T. Surgical approach and prognostic factors after peptic ulcer perforation. *Eur J Surg.* 1999;165(6):566-72. doi: 10.1080/110241599750006479. [PubMed: 10433141].
10. Rajesh V, Chandra SS, Smile SR. Risk factors predicting operative mortality in perforated peptic ulcer disease. *Trop Gastroenterol.* 2003;24(3):148-50. [PubMed: 14978992].
11. Buck DL, Moller MH, Danish Clinical Register of Emergency S. Influence of body mass index on mortality after surgery for perforated peptic ulcer. *Br J Surg.* 2014;101(8):993-9. doi: 10.1002/bjs.9529. [PubMed: 24828155].

12. Mouret P, Francois Y, Vignal J, Barth X, Lombard-Platet R. Laparoscopic treatment of perforated peptic ulcer. *Br J Surg*. 1990;77(9):1006. doi: [10.1002/bjs.1800770916](https://doi.org/10.1002/bjs.1800770916). [PubMed: [2145052](https://pubmed.ncbi.nlm.nih.gov/2145052/)].
13. Lau H. Laparoscopic repair of perforated peptic ulcer: a meta-analysis. *Surg Endosc*. 2004;18(7):1013-21. doi: [10.1007/s00464-003-8266-y](https://doi.org/10.1007/s00464-003-8266-y). [PubMed: [15136924](https://pubmed.ncbi.nlm.nih.gov/15136924/)].
14. Siu WT, Leong HT, Law BK, Chau CH, Li AC, Fung KH, et al. Laparoscopic repair for perforated peptic ulcer: a randomized controlled trial. *Ann Surg*. 2002;235(3):313-9. doi: [10.1097/0000658-200203000-00001](https://doi.org/10.1097/0000658-200203000-00001). [PubMed: [11882751](https://pubmed.ncbi.nlm.nih.gov/11882751/)].
15. Song KY, Kim TH, Kim SN, Park CH. Laparoscopic repair of perforated duodenal ulcers: the simple "one-stitch" suture with omental patch technique. *Surg Endosc*. 2008;22(7):1632-5. doi: [10.1007/s00464-007-9670-5](https://doi.org/10.1007/s00464-007-9670-5). [PubMed: [18030520](https://pubmed.ncbi.nlm.nih.gov/18030520/)].
16. Sanabria A, Villegas MI, Morales Uribe CH. Laparoscopic repair for perforated peptic ulcer disease. *Cochrane Database Syst Rev*. 2013(2):CD004778. doi: [10.1002/14651858.CD004778.pub3](https://doi.org/10.1002/14651858.CD004778.pub3). [PubMed: [23450555](https://pubmed.ncbi.nlm.nih.gov/23450555/)].
17. Bertleff MJ, Halm JA, Bemelman WA, van der Ham AC, van der Harst E, Oei HI, et al. Randomized clinical trial of laparoscopic versus open repair of the perforated peptic ulcer: the LAMA Trial. *World J Surg*. 2009;33(7):1368-73. doi: [10.1007/s00268-009-0054-y](https://doi.org/10.1007/s00268-009-0054-y). [PubMed: [19430829](https://pubmed.ncbi.nlm.nih.gov/19430829/)].
18. Bertleff MJ, Lange JF. Laparoscopic correction of perforated peptic ulcer: first choice? A review of literature. *Surg Endosc*. 2010;24(6):1231-9. doi: [10.1007/s00464-009-0765-z](https://doi.org/10.1007/s00464-009-0765-z). [PubMed: [20033725](https://pubmed.ncbi.nlm.nih.gov/20033725/)].
19. Kim JH, Chin HM, Bae YJ, Jun KH. Risk factors associated with conversion of laparoscopic simple closure in perforated duodenal ulcer. *Int J Surg*. 2015;15:40-4. doi: [10.1016/j.ijvsu.2015.01.028](https://doi.org/10.1016/j.ijvsu.2015.01.028). [PubMed: [25644542](https://pubmed.ncbi.nlm.nih.gov/25644542/)].
20. Wright GP, Davis AT, Koehler TJ, Scheeres DE. Cost-efficiency and outcomes in the treatment of perforated peptic ulcer disease: laparoscopic versus open approach. *Surgery*. 2014;156(4):1003-7. doi: [10.1016/j.surg.2014.06.047](https://doi.org/10.1016/j.surg.2014.06.047). [PubMed: [25239359](https://pubmed.ncbi.nlm.nih.gov/25239359/)].
21. Shelat VG, Ahmed S, Chia CL, Cheah YL. Strict Selection Criteria During Surgical Training Ensures Good Outcomes in Laparoscopic Omental Patch Repair (LOPR) for Perforated Peptic Ulcer (PPU). *Int Surg*. 2015;100(2):370-5. doi: [10.9738/INTSURG-D-13-00241.1](https://doi.org/10.9738/INTSURG-D-13-00241.1). [PubMed: [25692444](https://pubmed.ncbi.nlm.nih.gov/25692444/)].
22. Kuwabara K, Matsuda S, Fushimi K, Ishikawa KB, Horiguchi H, Fujimori K. Community-based evaluation of laparoscopic versus open simple closure of perforated peptic ulcers. *World J Surg*. 2011;35(11):2485-92. doi: [10.1007/s00268-011-1252-y](https://doi.org/10.1007/s00268-011-1252-y). [PubMed: [21915743](https://pubmed.ncbi.nlm.nih.gov/21915743/)].
23. Thorsen K, Glomsaker TB, von Meer A, Soreide K, Soreide JA. Trends in diagnosis and surgical management of patients with perforated peptic ulcer. *J Gastrointest Surg*. 2011;15(8):1329-35. doi: [10.1007/s11605-011-1482-1](https://doi.org/10.1007/s11605-011-1482-1). [PubMed: [21567292](https://pubmed.ncbi.nlm.nih.gov/21567292/)].
24. Gurusamy K, Aggarwal R, Palanivelu L, Davidson BR. Systematic review of randomized controlled trials on the effectiveness of virtual reality training for laparoscopic surgery. *Br J Surg*. 2008;95(9):1088-97. doi: [10.1002/bjs.6344](https://doi.org/10.1002/bjs.6344). [PubMed: [18690637](https://pubmed.ncbi.nlm.nih.gov/18690637/)].
25. Moorthy K, Munz Y, Dosis A, Bello F, Chang A, Darzi A. Bimodal assessment of laparoscopic suturing skills: construct and concurrent validity. *Surg Endosc*. 2004;18(11):1608-12. doi: [10.1007/s00464-003-9312-5](https://doi.org/10.1007/s00464-003-9312-5). [PubMed: [15931486](https://pubmed.ncbi.nlm.nih.gov/15931486/)].