

Minimally Invasive Video-Assisted Thyroidectomy (MIVAT) in the Era of Minimal Access Thyroid Surgery

Sohail Bakkar,^{1*} and Paolo Miccoli²

¹Department of Surgery, Faculty of Medicine, The Hashemite University, 13133 Zarqa, Jordan

²Division of Endocrine Surgery, Department of Surgical Pathology, University Hospital of Pisa, Via Paradisa 2, 56124 Pisa, Italy

*Corresponding author: Sohail Bakkar, Department of Surgery, Faculty of Medicine, The Hashemite University, 13133 Zarqa, Jordan. Tel: +39-3401439666, Fax: +39-50997709, E-mail: sohail.bakkar@gmail.com

Received 2016 September 21; Revised 2017 November 17; Accepted 2017 November 25.

Abstract

Background: In the era of minimal access thyroid surgery, the terms minimal access and minimally invasive are often used interchangeably and in most instances this is far from being accurate. The aim of this article is to examine the characteristics and potential of one of the first minimal access thyroid procedures described; minimally invasive video-assisted thyroidectomy (MIVAT).

Methods: The purpose of this article was obtained by almost two decades of experiences with the procedure at the authors' center, and a systemic literature review was undertaken of all available medical literature to evaluate available literature by conducting a PubMed search limited to articles originally written in English language between the years 1997 and 2016. The search was limited by using the terms: minimally invasive thyroid surgery, video-assisted, endoscopic, and robotic thyroidectomy. The procedure's design, radicality and safety, learning curve, cost, advantages and disadvantages were addressed. MIVAT's potential as a surgical tool for thyroid pathology was also addressed by evaluating its indications, contraindications, and limitations.

Results: MIVAT is a gasless hybrid procedure that is comparable to conventional thyroidectomy (CT) in terms of radicality and safety, with the added advantage of reduced early postoperative voice and swallowing symptoms. MIVAT has a relatively rapid learning curve with an additional advantage over other minimal access procedures; the ability of being adopted by the low-volume surgeon at a cost and time comparable to CT, but with improved patient satisfaction. Furthermore, it is non-inferior to procedures free of a neck scar in terms of patient satisfaction. MIVAT's main drawback is that it is limited by its strict selection criteria. It is a viable treatment option for all types of thyroid pathologies. However, its role in therapeutic neck dissection remains to be validated.

Conclusions: MIVAT is a safe and effective procedure which is obviously described in its name "minimally invasive". It seems that in the era of innovative technologies and scarless-in-the neck thyroid surgery, MIVAT is here to stay.

Keywords: Minimally Invasive Thyroid Surgery, Video-Assisted Thyroidectomy, Endoscopic Thyroidectomy, Robotic Thyroidectomy

1. Background

The concept of minimal access thyroid surgery (MATS) is an appealing one especially that a large proportion of patients are young women who may be equally concerned with cosmetic and therapeutic outcomes. In the era of MATS, the terms minimal access and minimally invasive are often used interchangeably and in most instances this is far from being accurate. The term minimally invasive often conveys a false impression regarding the extent of dissection performed. This particularly applies to procedures that involve extensive dissections similar to that of their conventional counterparts, but are performed through a small or hidden access. In such instances, minimal access would be a much more accurate descriptive term of reality.

MATS can be broadly classified into three categories: completely endoscopic, partly endoscopic, and non-endoscopic procedures. Non-endoscopic mini-incision

thyroidectomy is identical to conventional thyroidectomy in all of its executional steps; however, it is performed through a smaller incision. Purely endoscopic procedures are completed totally endoscopically, with or without gas insufflation, via different routes: the axilla, breast, lateral neck, anterior chest and both the breast and axilla combined (1). Most of these procedures could be considered remote-access procedures that offer patients a thyroid surgery free of a neck scar. Minimally invasive video-assisted thyroidectomy (MIVAT), first described in the late 1990s, is performed only partly endoscopically. It is a reproduction of conventional thyroidectomy (CT) in all of its procedural steps; however, it is executed differently (2) and despite of the considerable advancements in technology and the introduction of robotics into the field of surgery, MIVAT has maintained its popularity in the era of minimal access thyroid surgery. The purpose of this article is to examine MIVAT's characteristics and potential

objectively in comparison with time-honored CT and other minimal access procedures. This is conducted in light of almost 20 years of experience with the procedure and more than 2400 cases performed, as well as the current available literature.

The technical details of MIVAT have been thoroughly described in literature (2), and are demonstrated in the supplemented video.

MIVAT's Design

MIVAT is a hybrid procedure that is performed partly endoscopically and partly conventionally through a small central cervical access without CO₂ insufflation.

1.1. Gasless Procedure

The importance of being a gasless subplatysmal procedure cannot be overlooked as literature has demonstrated that prolonged CO₂ insufflation below the platysma is associated with sustained intravascular absorption and massive subcutaneous emphysema (3).

1.2. The Endoscopic Part

The magnified vision offered by the endoscope allows for the better visualization of key anatomic structures, namely the recurrent laryngeal nerve (RLN) and the parathyroid glands (4, 5) (Figure 1). It also allows for the visualization of the external branch of the superior laryngeal nerve (EBSLN) in most cases (Figure 2). Unlike the RLN, the EBSLN is not routinely identified in conventional thyroidectomy (CT). "I know where it should be, and I avoid it, but I have never seen it" is a statement commonly quoted by surgeons. However, as a basic surgical principle the best way to avoid injuring a structure is to identify it and preserve it. Berti et al. (6) reported a 65% identification rate of the EBSLN with MIVAT; they also reported identifying the anastomotic communication between the EBSLN and distal RLN. The magnified view of anatomic structures minimize the time and extent of dissection required for their identification which decrease the risk of contusion and ischemic injuries, theoretically. Nevertheless, it does not seem to convey any significant added benefit of safety (7) apart from a lower risk of early postoperative voice and swallowing symptoms (8).

1.3. The Conventional Part

MIVAT's direct access and conventional part are responsible for its comparability to CT in terms of radicality and safety. They also facilitate its learning curve.

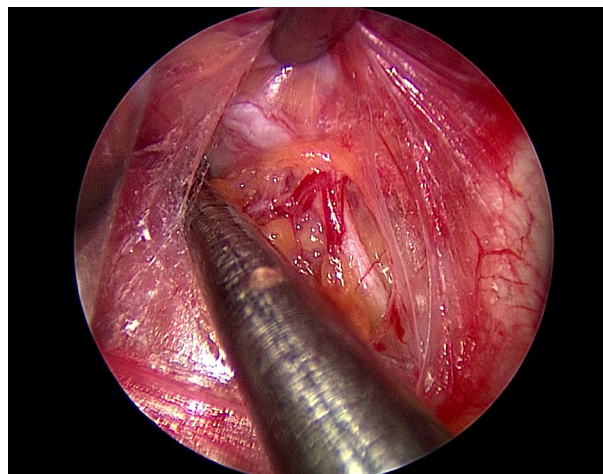


Figure 1. Endoscopic View of the Left Recurrent Laryngeal Nerve; the Nerve is Seen Crossing the Inferior Thyroid Artery Posteriorly

1.3.1. Radicality and Safety

Surgical incompleteness is a potential limitation of remote-access procedures regardless of the level of experience of the operator. In non-robotic endoscopic procedures, the design of endoscopic instruments in the setting of difficult-to-reach anatomic areas is a potential barrier to a complete resection (9, 10). Even after the introduction of the robot with the precise and multi-articulated wrist-like movements, it offers, complete removal of thyroid tissue is still compromised by the potential harm that the use of energy devices may inflict on the RLN and/or the parathyroids (11). MIVAT's design on the other hand allows it to be as radical as CT when its selection criteria are met without compromising its safety. In terms of safety, multi-center studies in Europe and North America demonstrated MIVAT's comparability to CT (12, 13). Furthermore, MIVAT does not have the potential for unprecedented complications introduced by other minimal access thyroid surgeries. Trans-axillary procedures for instance are associated with the risk of stretch injury to the brachial plexus, injury to the great vessels at the thoracic outlet, and aerodigestive injuries (14). The incision in the tail of the breast might have the impact on the efficacy of future mammograms or on the accuracy of sentinel node mapping is another worrisome aspect of the axillary access (15). Surgical track seeding of cancer cells following remote-access procedures is another potential complication that has no MIVAT analogue (16).

1.3.2. Learning Curve, Operative Time and Cost

MIVAT's direct access and conventional part, allow for attaining an adequate level of proficiency and safety per-

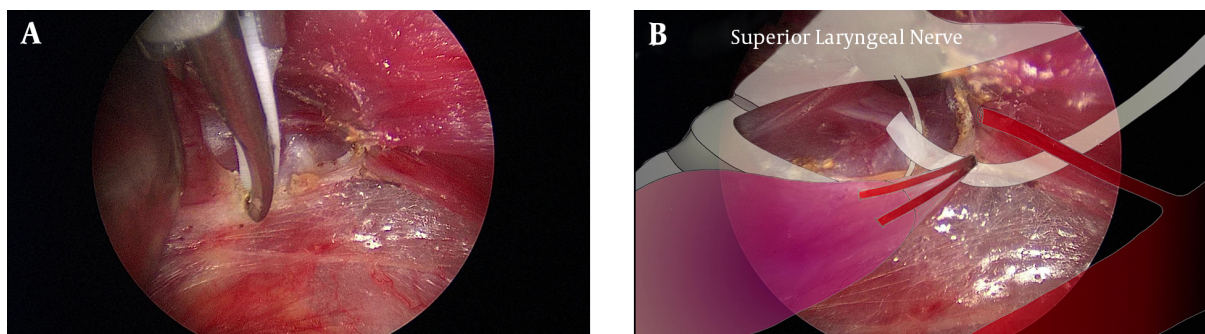


Figure 2. Dividing the Superior Thyroid Pedicle Using Ultrasonic Shears, A, the Inactive Blade (White) Is Directed Towards the Larynx to Minimize the Risk of Injuring the External Branch of the Superior Laryngeal Nerve (ESBLN); B, the ESBLN is Seen Crossing the Superior Thyroid Vessels 1 cm Above the Upper Pole of the Thyroid Lobe; a Structure Seldom Identified in Conventional Thyroidectomy

forming the procedure after only 30 operations (17,18). This is comparable to the learning curve of robotic thyroidectomy (35 - 40 operations); a procedure that benefits from a technology that offers surgeons improved ergonomics and dexterity, and is faster than that of non-robotic endoscopic thyroidectomy (55 - 60 operations) (19). MIVAT's learning curve could be further facilitated by a series of modifications made to the original procedure (20). This alteration allows it to be adopted by low-volume surgeons, unlike other minimal access thyroid procedures that are only embraced by high-volume centers. An adequate learning curve and the use of re-usable instruments allow MIVAT to be performed at a cost comparable to that of CT (21, 22) and with no significant added operative time (23-25). Although it has been reported that MIVAT requires a significantly longer time to perform in comparison to CT (7), the authors' vast experience with the procedure has demonstrated its comparability to CT in operative time. This is mainly attributed to three factors: an adequate learning curve in a high volume center that allows its sustainability, adhering to selection criteria, and the use of advanced energy devices. A dramatic reduction in operative time (more than 50%) following the introduction of energy devices has been demonstrated (26).

2. MIVAT's Advantages

The two advantages of MIVAT over CT that bring about improved patient satisfaction are its improved pain and cosmetic outcomes (27). A recent meta-analysis demonstrated that MIVAT patients experienced less pain during the entire postoperative period (7). Although reduced postoperative pain could not be considered as an additional advantage of MIVAT over CT (28), this advantage has been demonstrated objectively (29). Improved pain outcome was also demonstrated when MIVAT was compared

to non-endoscopic mini-incision thyroidectomy (30, 31). This reinforces the concept that surgical invasiveness is not only limited to the length of the incision but extends to every aspect of the procedure (32). The short incision in MIVAT is only a minor contributor to its minimal invasiveness which is mainly attributed to the targeted dissection offered by its direct access and endoscopic part. Unlike remote-access procedures, extensive and unnecessary dissections that label these procedures as "maximally invasive" (33) are avoided in MIVAT. This is probably the reason behind the surprising result obtained when MIVAT was compared to robot-assisted trans-axillary thyroidectomy. In an ironic twist, what was originally developed to be "a thyroid surgery free of a neck scar" was not superior to MIVAT in terms of patient's satisfaction (34). Furthermore, there is no unnatural neck extension, no subplatysmal flap elevation, and no strap muscle transection in MIVAT. Further testimony to MIVAT's true minimally invasive nature was provided by a recent meta-analysis that demonstrated a lower immune response to surgical trauma generated by MIVAT than by CT (35).

The superiority of MIVAT over CT in terms of cosmetic outcome remains contentious. While this has been demonstrated by many (7, 27) studies, others concluded that a shorter cervical scar was not associated with improved patient satisfaction (36-38). Furthermore, it may be argued that shorter incisions may compromise the safety of a procedure without favorably influencing patient satisfaction (39). Although this may apply to CT where all the critical steps of the procedure are conducted through the incision, it does not apply to MIVAT. In MIVAT, the incision mainly serves as a means for creating an adequate working space through which all the critical steps of the procedure are executed. In terms of cosmetic outcome it seems fair to say that MIVAT if not superior to CT, is at a minimum comparable to it. Nevertheless, patients are offered a comple-

mentary considerably shorter scar that would certainly be less visible on the long run (Figure 3).

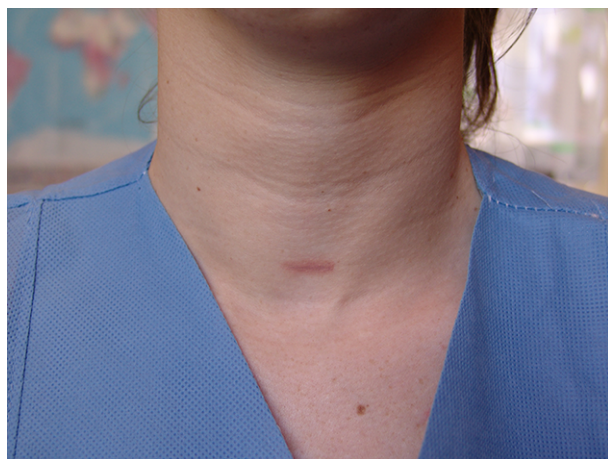

Figure 3. The Site of Surgery 2 Weeks Following Minimally Invasive Video-Assisted Thyroidectomy (MIVAT)

3. MIVAT's Disadvantages

MIVAT's main drawback is that its viability as a surgical option is limited by its strict selection criteria. It has been demonstrated in the literature that MIVAT could only be offered to a small proportion of patients. This is even more evident in areas of the world where iodine deficiency is endemic and a large thyroid volume is a major limitation. In the authors' experience only 15% of patients were candidates for the procedure (26). Lower figures (10% or less) have been reported from regions where goitre is endemic (37). Another disadvantage of MIVAT is that despite its satisfying long-term cosmetic outcomes, it is not protective against keloids (40, 41). Furthermore, the potential adverse sequelae of any incision are visible if they occur. Nevertheless, MIVAT's benefits seem to outweigh its potential drawbacks.

Misconceptions about a surgical procedure limit its global spread and could be considered as a potential disadvantage that is not inherent to the procedure itself (42). Some surgeons falsely believe that adopting MIVAT requires extensive additional training, and is associated with a heavy financial burden. Others do not appreciate its true minimally invasive nature, and consider it a procedure performed through a small incision that could be performed conventionally through the same incision. These issues have been clarified in this article.

4. Indications and Contraindications of MIVAT

The evolution of MIVAT has been dramatic. It started off as a procedure surrounded by scepticism and limited to the treatment of single indeterminate nodules and benign thyroid pathologies, and has ultimately become a "surgical tool" for all types of thyroid pathologies within the confines of its selection criteria (2) (Table 1). The oncologic safety of MIVAT in low- and intermediate-risk well differentiated thyroid cancer has been demonstrated (43, 44). Being a minimal access, minimally invasive surgical intervention, and a viable treatment option for thyroid cancer, has favorable implications in terms of patient satisfaction particularly that thyroid cancer has the highest increase in incidence rate among all cancers (45) and that the vast majority of patients tend to be young women. This also applies to RET proto-oncogen point mutation carriers (46) who represent a group of young patients that require a total thyroidectomy despite not yet having clinically detectable disease. These patients may be less reluctant to accept prophylactic thyroidectomy if offered MIVAT instead of CT.

Table 1. Selection Criteria for Minimally Invasive Video-Assisted Thyroidectomy (MIVAT)

Absolute Contraindications	Relative Contraindications
Sonographically estimated thyroid volume > 30 mL	Thyroiditis
Benign nodules > 3.5 cm	Hyperthyroidism
Malignant lesions > 2 cm	Previous neck irradiation therapy
Previous neck surgery	Isthmic/ Para-isthmic nodules
High risk differentiated thyroid carcinoma	Obese patients
Clinically apparent nodal involvement	Patients with short necks

The comparability of MIVAT to CT in terms of effectiveness and safety for thyroidectomy accompanied by a prophylactic central neck dissection has been demonstrated (47). MIVAT's successfulness in therapeutic selective compartment oriented neck dissection has also been demonstrated (48). Nevertheless, it is only scientifically correct to consider therapeutic neck dissection by means of minimally invasive video-assisted techniques experimental, as confirming oncologic effectiveness requires further studies with larger numbers of patients and longer follow up.

The importance of adhering to selection criteria should not be taken lightly, as it is the key to success in any surgical procedure. The largest MIVAT series from North America has recently demonstrated that MIVAT is associated with fewer overall complications in comparison to CT, and that this is attributed to acknowledging the highly

selective nature of the procedure (49).

5. Conclusion

The popularity of MATS arises from the contemporary endocrine surgeon's need to offer patients a surgical approach that is tailored to their concerns and desires. MIVAT meets this need without compromising its primary objective of being an effective and safe therapeutic modality. MIVAT seems to offer a major additional advantage over other minimal access procedures; a reduction in the degree of surgical invasiveness. It is primarily a minimally invasive procedure that is performed through a minimal access.

Acknowledgments

Dr Marco Biricotti's work in preparing the video is highly appreciated.

Footnotes

Financial Disclosure: The authors have no conflicts of interest or financial ties to disclose

Consent: The patient's consent was obtained regarding videoring of her procedure, and its use for scientific purposes.

References

- Kazi R, Katna R, Dwivedi RC. Minimal access thyroid surgery - a new dawn?. *Ann R Coll Surg Engl*. 2010;**92**(5):361-2. doi: [10.1308/003588410X12699663903755](https://doi.org/10.1308/003588410X12699663903755). [PubMed: [20626967](https://pubmed.ncbi.nlm.nih.gov/20626967/)].
- Bakkar S, Materazzi G, Biricotti M, De Napoli L, Conte M, Galleri D, et al. Minimally invasive video-assisted thyroidectomy (MIVAT) from A to Z. *Surg Today*. 2016;**46**(2):255-9. doi: [10.1007/s00595-015-1241-0](https://doi.org/10.1007/s00595-015-1241-0). [PubMed: [26321206](https://pubmed.ncbi.nlm.nih.gov/26321206/)].
- Gottlieb A, Sprung J, Zheng XM, Gagner M. Massive subcutaneous emphysema and severe hypercarbia in a patient during endoscopic transcervical parathyroidectomy using carbon dioxide insufflation. *Anesth Analg*. 1997;**84**(5):1154-6. doi: [10.1213/00000539-199705000-00040](https://doi.org/10.1213/00000539-199705000-00040). [PubMed: [9141952](https://pubmed.ncbi.nlm.nih.gov/9141952/)].
- Huscher CS, Chiodini S, Napolitano C, Recher A. Endoscopic right thyroid lobectomy. *Surg Endosc*. 1997;**11**(8):877. doi: [10.1007/s004649900476](https://doi.org/10.1007/s004649900476). [PubMed: [9266657](https://pubmed.ncbi.nlm.nih.gov/9266657/)].
- Henry JF. Minimally invasive surgery of the thyroid and parathyroid glands. *Br J Surg*. 2006;**93**(1):1-2. doi: [10.1002/bjs.5199](https://doi.org/10.1002/bjs.5199). [PubMed: [16372392](https://pubmed.ncbi.nlm.nih.gov/16372392/)].
- Berti P, Materazzi G, Conte M, Galleri D, Miccoli P. Visualization of the external branch of the superior laryngeal nerve during video-assisted thyroidectomy. *J Am Coll Surg*. 2002;**195**(4):573-4. doi: [10.1016/S1072-7515\(02\)01338-8](https://doi.org/10.1016/S1072-7515(02)01338-8). [PubMed: [12375766](https://pubmed.ncbi.nlm.nih.gov/12375766/)].
- Pisanu A, Podda M, Reccia I, Porceddu G, Ucheddu A. Systematic review with meta-analysis of prospective randomized trials comparing minimally invasive video-assisted thyroidectomy (MIVAT) and conventional thyroidectomy (CT). *Langenbecks Arch Surg*. 2013;**398**(8):1057-68. doi: [10.1007/s00423-013-1125-y](https://doi.org/10.1007/s00423-013-1125-y). [PubMed: [24162166](https://pubmed.ncbi.nlm.nih.gov/24162166/)].
- Lombardi CP, Raffaelli M, D'Alatri L, De Crea C, Marchese MR, Maccora D, et al. Video-assisted thyroidectomy significantly reduces the risk of early postthyroidectomy voice and swallowing symptoms. *World J Surg*. 2008;**32**(5):693-700. doi: [10.1007/s00268-007-9443-2](https://doi.org/10.1007/s00268-007-9443-2). [PubMed: [18259807](https://pubmed.ncbi.nlm.nih.gov/18259807/)].
- Kandil EH, Noureldine SI, Yao L, Slakey DP. Robotic transaxillary thyroidectomy: an examination of the first one hundred cases. *J Am Coll Surg*. 2012;**214**(4):558-64. doi: [10.1016/j.jamcollsurg.2012.01.002](https://doi.org/10.1016/j.jamcollsurg.2012.01.002). [PubMed: [22360981](https://pubmed.ncbi.nlm.nih.gov/22360981/)] discussion 564-6.
- Lu JH, Materazzi G, Miccoli M, Baggiani A, Hu S, Miccoli P. Minimally invasive video assisted thyroidectomy versus endoscopic thyroidectomy via the areola approach: a retrospective analysis of safety, postoperative recovery, and patient satisfaction. *Minerva Chir*. 2012;**67**(1):31-7. [PubMed: [22361674](https://pubmed.ncbi.nlm.nih.gov/22361674/)].
- Perrier ND. Why I have abandoned robot-assisted transaxillary thyroid surgery. *Surgery*. 2012;**152**(6):1025-6. doi: [10.1016/j.surg.2012.08.060](https://doi.org/10.1016/j.surg.2012.08.060). [PubMed: [23158176](https://pubmed.ncbi.nlm.nih.gov/23158176/)].
- Miccoli P, Bellantone R, Mourad M, Walz M, Raffaelli M, Berti P. Minimally invasive video-assisted thyroidectomy: multiinstitutional experience. *World J Surg*. 2002;**26**(8):972-5. doi: [10.1007/s00268-002-6627-7](https://doi.org/10.1007/s00268-002-6627-7). [PubMed: [12016476](https://pubmed.ncbi.nlm.nih.gov/12016476/)].
- Terris DJ, Angelos P, Steward DL, Simental AA. Minimally invasive video-assisted thyroidectomy: a multi-institutional North American experience. *Arch Otolaryngol Head Neck Surg*. 2008;**134**(1):81-4. doi: [10.1001/archoto.2007.22](https://doi.org/10.1001/archoto.2007.22). [PubMed: [18209142](https://pubmed.ncbi.nlm.nih.gov/18209142/)].
- Sun GH, Peress L, Pynnonen MA. Systematic review and meta-analysis of robotic vs conventional thyroidectomy approaches for thyroid disease. *Otolaryngol Head Neck Surg*. 2014;**150**(4):520-32. doi: [10.1177/0194599814521779](https://doi.org/10.1177/0194599814521779). [PubMed: [24500878](https://pubmed.ncbi.nlm.nih.gov/24500878/)].
- Shaha AR. Transaxillary thyroidectomy-A critical appraisal. *J Surg Oncol*. 2015;**111**(2):131-2. doi: [10.1002/jso.23831](https://doi.org/10.1002/jso.23831). [PubMed: [2541137](https://pubmed.ncbi.nlm.nih.gov/2541137/)].
- Bakkar S, Frustaci G, Papini P, Fregoli L, Matteucci V, Materazzi G, et al. Track Recurrence After Robotic Transaxillary Thyroidectomy: A Case Report Highlighting the Importance of Controlled Surgical Indications and Addressing Unprecedented Complications. *Thyroid*. 2016;**26**(4):559-61. doi: [10.1089/thy.2015.0561](https://doi.org/10.1089/thy.2015.0561). [PubMed: [26850129](https://pubmed.ncbi.nlm.nih.gov/26850129/)].
- Miccoli P, Materazzi G, Ambrosini CE, Berti P. Minimally invasive surgery of the thyroid. *Eur Surg*. 2006;**38**(3):160-3. doi: [10.1007/s10353-006-0241-0](https://doi.org/10.1007/s10353-006-0241-0).
- Pons Y, Verillaud B, Blancal JP, Sauvaget E, Cloutier T, Le Clerc N, et al. Minimally invasive video-assisted thyroidectomy: Learning curve in terms of mean operative time and conversion and complication rates. *Head Neck*. 2013;**35**(8):1078-82. doi: [10.1002/hed.23081](https://doi.org/10.1002/hed.23081). [PubMed: [22791472](https://pubmed.ncbi.nlm.nih.gov/22791472/)].
- Lee J, Yun JH, Nam KH, Soh EY, Chung WY. The learning curve for robotic thyroidectomy: a multicenter study. *Ann Surg Oncol*. 2011;**18**(1):226-32. doi: [10.1245/s10434-010-1220-z](https://doi.org/10.1245/s10434-010-1220-z). [PubMed: [20680695](https://pubmed.ncbi.nlm.nih.gov/20680695/)].
- Terris DJ, Seybt MW. Modifications of Miccoli minimally invasive thyroidectomy for the low-volume surgeon. *Am J Otolaryngol*. 2011;**32**(5):392-7. doi: [10.1016/j.amjoto.2010.07.014](https://doi.org/10.1016/j.amjoto.2010.07.014). [PubMed: [20832901](https://pubmed.ncbi.nlm.nih.gov/20832901/)].
- Lombardi CP, Raffaelli M, Princi P, De Crea C, Bellantone R. Video-assisted thyroidectomy: report of a 7-year experience in Rome. *Langenbecks Arch Surg*. 2006;**391**(3):174-7. doi: [10.1007/s00423-006-0023-y](https://doi.org/10.1007/s00423-006-0023-y). [PubMed: [16528568](https://pubmed.ncbi.nlm.nih.gov/16528568/)].
- Byrd JK, Nguyen SA, Ketcham A, Hornig J, Gillespie MB, Lentsch E. Minimally invasive video-assisted thyroidectomy versus conventional thyroidectomy: a cost-effective analysis. *Otolaryngol Head Neck Surg*. 2010;**143**(6):789-94. doi: [10.1016/j.otohns.2010.08.002](https://doi.org/10.1016/j.otohns.2010.08.002). [PubMed: [21109079](https://pubmed.ncbi.nlm.nih.gov/21109079/)].
- Miccoli P, Berti P, Raffaelli M, Materazzi G, Conte M, Galleri D. Impact of harmonic scalpel on operative time during video-assisted thyroidectomy. *Surg Endosc*. 2002;**16**(4):663-6. doi: [10.1007/s00464-001-9117-3](https://doi.org/10.1007/s00464-001-9117-3). [PubMed: [11972210](https://pubmed.ncbi.nlm.nih.gov/11972210/)].

24. Dobrinja C, Trevisan G, Makovac P, Liguori G. Minimally invasive video-assisted thyroidectomy compared with conventional thyroidectomy in a general surgery department. *Surg Endosc*. 2009;**23**(10):2263-7. doi: [10.1007/s00464-008-0303-4](https://doi.org/10.1007/s00464-008-0303-4). [PubMed: [19184215](https://pubmed.ncbi.nlm.nih.gov/19184215/)].
25. Fan Y, Guo B, Guo S, Kang J, Wu B, Zhang P, et al. Minimally invasive video-assisted thyroidectomy: experience of 300 cases. *Surg Endosc*. 2010;**24**(10):2393-400. doi: [10.1007/s00464-010-0960-y](https://doi.org/10.1007/s00464-010-0960-y). [PubMed: [20177913](https://pubmed.ncbi.nlm.nih.gov/20177913/)].
26. Miccoli P, Biricotti M, Matteucci V, Ambrosini CE, Wu J, Materazzi G. Minimally invasive video-assisted thyroidectomy: reflections after more than 2400 cases performed. *Surg Endosc*. 2016;**30**(6):2489-95. doi: [10.1007/s00464-015-4503-4](https://doi.org/10.1007/s00464-015-4503-4). [PubMed: [26335076](https://pubmed.ncbi.nlm.nih.gov/26335076/)].
27. Radford PD, Ferguson MS, Magill JC, Karthikesalingham AP, Alusi G. Meta-analysis of minimally invasive video-assisted thyroidectomy. *Laryngoscope*. 2011;**121**(8):1675-81. doi: [10.1002/lary.21864](https://doi.org/10.1002/lary.21864). [PubMed: [21792954](https://pubmed.ncbi.nlm.nih.gov/21792954/)].
28. Alesina PF, Rolfs T, Ruhland K, Brunkhorst V, Groeben H, Walz MK. Evaluation of postoperative pain after minimally invasive video-assisted and conventional thyroidectomy: results of a prospective study. ESES Vienna presentation. *Langenbecks Arch Surg*. 2010;**395**(7):845-9. doi: [10.1007/s00423-010-0688-0](https://doi.org/10.1007/s00423-010-0688-0). [PubMed: [20628756](https://pubmed.ncbi.nlm.nih.gov/20628756/)].
29. Miccoli P, Rago R, Massi M, Panicucci E, Metelli MR, Berti P, et al. Standard versus video-assisted thyroidectomy: objective postoperative pain evaluation. *Surg Endosc*. 2010;**24**(10):2415-7. doi: [10.1007/s00464-010-0964-7](https://doi.org/10.1007/s00464-010-0964-7). [PubMed: [20195641](https://pubmed.ncbi.nlm.nih.gov/20195641/)].
30. O' Neill JP, Timon C, Agarwal A. Prospective assessment of postoperative pain in patients undergoing minimally invasive video-assisted versus minimally invasive open thyroidectomy. *World J Endocrine Surg*. 2011;**3**:11-4. doi: [10.5005/jip-journals-10002-1047](https://doi.org/10.5005/jip-journals-10002-1047).
31. Fik Z, Astl J, Zabrodsky M, Lukes P, Merunka I, Betka J, et al. Minimally invasive video-assisted versus minimally invasive nonendoscopic thyroidectomy. *Biomed Res Int*. 2014;**2014**:450170. doi: [10.1155/2014/450170](https://doi.org/10.1155/2014/450170). [PubMed: [24800227](https://pubmed.ncbi.nlm.nih.gov/24800227/)].
32. Henry JF. Minimally invasive thyroid and parathyroid surgery is not a question of length of the incision. *Langenbecks Arch Surg*. 2008;**393**(5):621-6. doi: [10.1007/s00423-008-0406-3](https://doi.org/10.1007/s00423-008-0406-3). [PubMed: [18716792](https://pubmed.ncbi.nlm.nih.gov/18716792/)].
33. Tan CT, Cheah WK, Delbridge L. "Scarless" (in the neck) endoscopic thyroidectomy (SET): an evidence-based review of published techniques. *World J Surg*. 2008;**32**(7):1349-57. doi: [10.1007/s00268-008-9555-3](https://doi.org/10.1007/s00268-008-9555-3). [PubMed: [18360737](https://pubmed.ncbi.nlm.nih.gov/18360737/)].
34. Materazzi G, Fregoli L, Manzini G, Baggiani A, Miccoli M, Miccoli P. Cosmetic result and overall satisfaction after minimally invasive video-assisted thyroidectomy (MIVAT) versus robot-assisted transaxillary thyroidectomy (RATT): a prospective randomized study. *World J Surg*. 2014;**38**(6):1282-8. doi: [10.1007/s00268-014-2483-5](https://doi.org/10.1007/s00268-014-2483-5). [PubMed: [24615602](https://pubmed.ncbi.nlm.nih.gov/24615602/)].
35. Zheng C, Liu S, Geng P, Zhang H, Zhang H, Tang A, et al. Minimally invasive video-assisted versus conventional open thyroidectomy on immune response: a meta analysis. *Int J Clin Exp Med*. 2015;**8**(2):2593-9. [PubMed: [25932206](https://pubmed.ncbi.nlm.nih.gov/25932206/)].
36. O'Connell DA, Diamond C, Seikaly H, Harris JR. Objective and subjective scar aesthetics in minimal access vs conventional access parathyroidectomy and thyroidectomy surgical procedures: a paired cohort study. *Arch Otolaryngol Head Neck Surg*. 2008;**134**(1):85-93. doi: [10.1001/archotol.134.1.85](https://doi.org/10.1001/archotol.134.1.85). [PubMed: [18209143](https://pubmed.ncbi.nlm.nih.gov/18209143/)].
37. Bokor T, Kiffner E, Kotrikova B, Billmann F. Cosmesis and body image after minimally invasive or open thyroid surgery. *World J Surg*. 2012;**36**(6):1279-85. doi: [10.1007/s00268-012-1563-7](https://doi.org/10.1007/s00268-012-1563-7). [PubMed: [22407089](https://pubmed.ncbi.nlm.nih.gov/22407089/)].
38. Linos D, Economopoulos KP, Kiriakopoulos A, Linos E, Petralias A. Scar perceptions after thyroid and parathyroid surgery: comparison of minimal and conventional approaches. *Surgery*. 2013;**153**(3):400-7. doi: [10.1016/j.surg.2012.08.008](https://doi.org/10.1016/j.surg.2012.08.008). [PubMed: [22980435](https://pubmed.ncbi.nlm.nih.gov/22980435/)].
39. Toll EC, Loizou P, Davis CR, Porter GC, Pothier DD. Scars and satisfaction: do smaller scars improve patient-reported outcome?. *Eur Arch Otorhinolaryngol*. 2012;**269**(1):309-13. doi: [10.1007/s00405-011-1613-z](https://doi.org/10.1007/s00405-011-1613-z). [PubMed: [21544658](https://pubmed.ncbi.nlm.nih.gov/21544658/)].
40. Sahn M, Schwarz B, Schmidt S, Pross M, Lippert H. Long-term cosmetic results after minimally invasive video-assisted thyroidectomy. *Surg Endosc*. 2011;**25**(10):3202-8. doi: [10.1007/s00464-011-1693-2](https://doi.org/10.1007/s00464-011-1693-2). [PubMed: [21487856](https://pubmed.ncbi.nlm.nih.gov/21487856/)].
41. Ikeda Y, Takami H, Sasaki Y, Takayama J, Kurihara H. Are there significant benefits of minimally invasive endoscopic thyroidectomy?. *World J Surg*. 2004;**28**(11):1075-8. doi: [10.1007/s00268-004-7655-2](https://doi.org/10.1007/s00268-004-7655-2). [PubMed: [15490052](https://pubmed.ncbi.nlm.nih.gov/15490052/)].
42. Bakkar S, Materazzi G. Posterior retroperitoneoscopic adrenalectomy; how to do it - pearls and secrets. *J Minim Invasive Surg Sci*. 2016;**5**(4) doi: [10.17795/minisurgery-42362](https://doi.org/10.17795/minisurgery-42362).
43. Miccoli P, Pinchera A, Materazzi G, Biagini A, Berti P, Faviana P, et al. Surgical treatment of low- and intermediate-risk papillary thyroid cancer with minimally invasive video-assisted thyroidectomy. *J Clin Endocrinol Metab*. 2009;**94**(5):1618-22. doi: [10.1210/jc.2008-1418](https://doi.org/10.1210/jc.2008-1418). [PubMed: [19223525](https://pubmed.ncbi.nlm.nih.gov/19223525/)].
44. Del Rio P, Maestroni U, Sianesi M, Viani L, Vicente D, Stojadinovic A, et al. Minimally invasive video-assisted thyroidectomy for papillary thyroid cancer: a prospective 5-year follow-up study. *Tumori*. 2015;**101**(2):144-7. doi: [10.5301/tj.5000223](https://doi.org/10.5301/tj.5000223). [PubMed: [25791536](https://pubmed.ncbi.nlm.nih.gov/25791536/)].
45. Morris LG, Myssiorek D. Improved detection does not fully explain the rising incidence of well-differentiated thyroid cancer: a population-based analysis. *Am J Surg*. 2010;**200**(4):454-61. doi: [10.1016/j.amjsurg.2009.11.008](https://doi.org/10.1016/j.amjsurg.2009.11.008). [PubMed: [20561605](https://pubmed.ncbi.nlm.nih.gov/20561605/)].
46. Miccoli P, Elisei R, Berti P, Materazzi G, Agate L, Castagna MG, et al. Video assisted prophylactic thyroidectomy and central compartment nodes clearance in two RET gene mutation adult carriers. *J Endocrinol Invest*. 2004;**27**(6):557-61. doi: [10.1007/BF03347478](https://doi.org/10.1007/BF03347478). [PubMed: [15717653](https://pubmed.ncbi.nlm.nih.gov/15717653/)].
47. Hensler MS, Falciglia M, Yaqub A, Yang H, Steward DL. Elective central node dissection: Comparison of open to minimally invasive video-assisted approach. *Laryngoscope*. 2016;**126**(7):1715-8. doi: [10.1002/lary.25844](https://doi.org/10.1002/lary.25844). [PubMed: [26928077](https://pubmed.ncbi.nlm.nih.gov/26928077/)].
48. Wu B, Ding Z, Fan Y, Deng X, Guo B, Kang J, et al. Video-assisted selective lateral neck dissection for papillary thyroid carcinoma. *Langenbecks Arch Surg*. 2013;**398**(3):395-401. doi: [10.1007/s00423-012-1045-2](https://doi.org/10.1007/s00423-012-1045-2). [PubMed: [23494581](https://pubmed.ncbi.nlm.nih.gov/23494581/)].
49. Duke WS, White JR, Waller JL, Terris DJ. Six-Year Experience With Endoscopic Thyroidectomy: Outcomes and Safety Profile. *Ann Otol Rhinol Laryngol*. 2015;**124**(11):915-20. doi: [10.1177/0003489415591837](https://doi.org/10.1177/0003489415591837). [PubMed: [26082473](https://pubmed.ncbi.nlm.nih.gov/26082473/)].