

# PCO MMESA First Menstruation After Delivery in an Infertile Sudanese Patient With Polycystic Ovarian Syndrome

Wisal Omer Mohamed Nabag<sup>1,\*</sup>; Mohamed Ahmed Ali El Sheikh<sup>2</sup>

<sup>1</sup>Department of Obstetrics and Gynecology, Alziem ALazhari University, Khartoum, Sudan

<sup>2</sup>Department of Obstetrics and Gynecology, University of Khartoum, Khartoum, Sudan

\*Corresponding author: Wisal Omer Mohamed Nabag, Department of Obstetrics and Gynecology, Alziem ALazhari University, Khartoum, Sudan. Tel: +249-21583983, E-mail: wisnab3@yahoo.com

Received: July 3, 2013; Accepted: July 17, 2013

**Introduction:** Primary Amenorrhea is a condition in which a young woman has not started her menstrual periods by the age of 16-18. The principal features of polycystic ovarian syndrome (PCOS) are anovulation, resulting in irregular menstruation, amenorrhea, and ovulation-related infertility.

**Case Presentation:** From January 2007 to June 2013 we conducted 2215 laparoscopies, out of which 605 (27.6%) were infertile patients with PCOS who underwent Laparoscopy procedure as day surgery in the standard method under general anesthesia; among these patients one case had primary amenorrhea and infertility.

**Conclusions:** A twenty-two years obese patient referred to us with acne and hirsutism. PCO was diagnosed by ultrasound & confirmed by laparoscopy. Laparoscopic findings showed normal uterus and patent tubes. Ovarian drilling was done after 6 months of conservative management. 3 months after the drilling the patient was conceived, delivered a full term baby and was menstruating for the first time 6 weeks after her delivery. PCOS is one of the most common female endocrine disorders. The patient underwent laparoscopy and ovarian drilling followed by clomiphene plus metformin and finally she conceived and regained her first cycle after her delivery. The reason could be that the drilling decreases the level of androgen, metformin makes the cells more sensitive to insulin and clomiphene increases the chance of ovulation as well. Clinicians in Sudan must consider PCOS as an important cause of primary amenorrhea and a common cause of primary infertility.

**Keywords:** Polycystic Ovarian Syndrome; Amenorrhea; Infertility; Laparoscopy

## 1. Introduction

Primary Amenorrhea describes a condition in which a young woman has not started her menstrual periods by the age of 16-18. When a woman does not begin her normal menstrual cycles, it should be a matter of concern. There are quite a few reasons for this condition, such as being born with poorly formed genitalia or other pelvic organs (missing uterus or vagina, vaginal septum, cervical stenosis, or imperforate hymen) which can lead to primary amenorrhea (1). Hormones play a fundamental role in a woman's menstrual cycle. Hormonal problems may occur when: the parts of the brain producing the hormones that help manage the menstrual cycle are altered and the ovaries are thereto not working correctly. One of the most common hormonal problems is polycystic ovarian syndrome (PCOS). Its international prevalence is 4-12% (2) and is considered as the first cause for female infertility, according to the Centers for Disease Control and Prevention's announcements (3). It is also closely linked to insulin resistance and glucose cycle problems. The symptoms and severity of PCOS vary greatly among affected

women (4). High levels of androgenic hormones interfere with the pituitary ovarian axis, leading to increased LH levels, anovulation, amenorrhea, and infertility (5). For overweight, anovulated women with PCOS, weight loss and diet adjustment are associated with resumption of natural ovulation. For those who are lean or anovulatory even after weight loss, the principal treatment to promote ovulation would be clomiphene citrate (6) and follicle stimulating hormone (FSH) (7). Metformin (the anti-diabetes medication) was recommended (8). Ovarian diathermy is a surgical treatment and is thought to reduce the amount of androgen secreting tissue in the ovaries leading to resumption of ovulation in up to 80% of women lasting six to nine months (9).

## 2. Case Presentation

Patients were usually referred to the Minimal Access Gynecological Surgery (MAGS) from Omdurman Maternity Hospital or other local hospitals, Family Control Clinics and private sector for laparoscopy one patient had pri-

### Implication for health policy/practice/research/medical education:

This is a case report to certify that from January 2007 to June 2013 we conducted 2215 laparoscopies, out of which 605 (27.6%) were infertile patients with PCOS who underwent Laparoscopy procedure Among these patients one case had primary amenorrhea and infertility. Laparoscopy was conducted for this case in January 2012

Copyright © 2014, Minimally Invasive Surgery Research Center and Mediterranean & Middle Eastern Endoscopic Surgery Association. This is an open-access article distributed under the terms of the Creative Commons Attribution License, which permits unrestricted use, distribution, and reproduction in any medium, provided the original work is properly cited.

mary amenorrhea and infertility. Standard laparoscopy was performed as day surgery under general anesthesia. Then clomiphene and metformin were prescribed. The patients were followed after 6 months and one year.

A twenty-two years infertile patient was referred to us from west of Sudan as a case of primary amenorrhea and infertility. She was married to a 30 year-old healthy Sudanese man, a farmer, for 5 years and they had normal marital relationship. Examination revealed that the patient was obese, a well feminized female with normal secondary sex characters, hirsutism, and acne. Her Body Mass Index (BMI) was 30 kg/m<sup>2</sup>. No abnormalities were detected in abdominal as well as breast examination. Per vaginal (PV) examination revealed normal vagina, anteverted uterus, and free adnexae. Seminal analysis was normal, hormonal profile revealed normal level of LH and FSH and high prolactin level. Fasting blood sugar was within the normal range (85 mg/dl). Ultrasound revealed normal empty anteverted uterus, and polycystic ovaries (PCO). PCO, which is commonly diagnosed by means of 12 or more 2-9 mm follicles, or increased ovarian volume (> 10 cm<sup>3</sup>) as shown in Figure 1. So we advised the patient to reduce her weight and change her life style. 6 months later there was no menstruation or pregnancy. Laparoscopy was performed. The laparoscopic findings revealed a normal sized anteverted uterus. And PCO, Pelvic adhesions, per tubal, per ovarian, massive pelvic adhesions, frozen pelvis, per portal adhesions and endometriosis were not found her tubes were patent, confirmed with free spillage of methylene blue dye from the fimbrial ends. The white capsules of the ovaries are thickened and the ovaries are often very rounded. The ovaries were punctured on 4 points with electro cautery (as shown in Figure 2) and then clomi-phene and metformin were prescribed for 6 months, with follow-up regarding her cycle and pregnancy. After 3 months of follow-up no menstruation or pregnancy was reported. Three months after that the patient was pregnant. Her pregnancy was passed uneventful and she delivered vaginally a full term male baby alive and well. Six weeks after delivery, she experienced her first menstrual cycle. PCOS is one of the most common female endocrine disorders. PCOS is a complex, heterogeneous disorder of uncertain etiology. Its symptoms occur in approximately 5% to 10% of women of reproductive age (12-45 years old) ranging from anovulation, obesity, biochemical or clinical hyper androgenism and insulin resistance. The World Health Organization criteria for classification of anovulation include the determination of oligomenorrhea (menstrual cycle > 35 days) or amenorrhea (menstrual cycle > 6 months) in combination with concentration of prolactin, FSH and estradiol.

### 3. Discussion

PCOS is the most common cause of anovulation in women with normal serum FSH and estradiol levels (10). Despite the heterogeneity in symptoms associated with PCOS, the essential feature is arrested follicular develop-

ment at the stage when selection of the dominant follicle should normally occur (11). In a normal menstrual cycle, one egg is released from a dominant follicle-essentially a cyst that bursts to release the egg. After ovulation the remnant follicle is transformed into a progesterone-producing corpus luteum, which shrinks and disappears after approximately 12-14 days. In PCOS, there is a so-called "follicular arrest", i.e. several follicles develop to a size of 5-7 mm, but not further. No single follicle reaches the preovulatory size (16 mm or more). The small ovarian follicles are believed to be the result of disturbed ovarian function resulting in failed ovulation, reflected by the infrequent or absent menstruation that is typical of the condition with normal LH level.

The principal features of PCOS are anovulation, resulting in irregular menstruation, amenorrhea, ovulation-related infertility, and polycystic ovaries. The main features of our patient, including primary amenorrhea, infertility and ultrasound (U/S) report, as well as laparoscopy con-

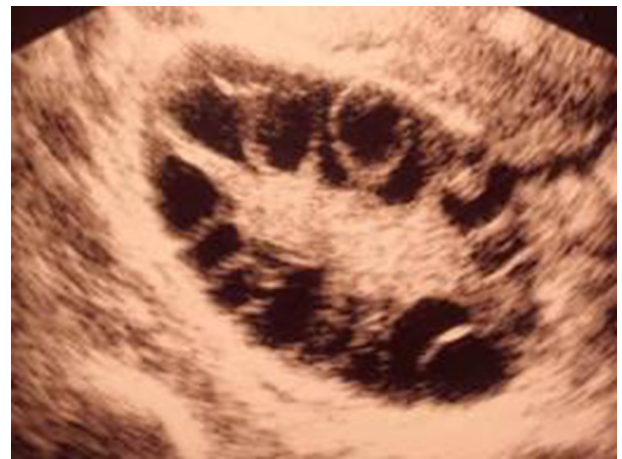

Figure 1. Ultrasound Picture of PCO

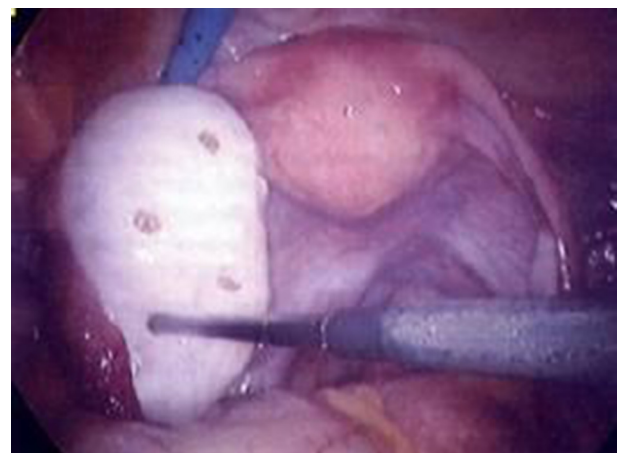


Figure 2. Laparoscopic Picture of PCO and Drilling

firmed the diagnosis of PCO. The patient had also acne and hirsutism; resulting from excessive amounts of androgenic hormones. Women with PCOS have an increased risk of developing type 2 diabetes. However, before the onset of diabetes, the blood sugar is usually under control. Our case had also normal fasting blood sugar (85mg/dl). As such, it is normal for a woman with PCOS to have a fasting blood sugar of 85 to 100 mg/dL, which lies within the normal range of less than 100 mg/dL (12).

The chance of becoming pregnant depends on how often the patient ovulates. Some women with PCOS ovulate now and then, others not at all. Metformin is a drug that is commonly used to treat type 2 diabetes. It makes the body's cells more sensitive to insulin (10). This may result in a decrease in the blood level of insulin which may help to counteract the underlying cause of PCOS and then increase the chance of ovulation. The United Kingdom's National Institute for Health and Clinical Excellence recommended in 2004 that women suffering from PCOS with a BMI above 25 be given metformin when other therapy has failed to produce preferable results (13). The patient was not menstruate or conceived after diet, lifestyle and clomiphene therapy; so she underwent laparoscopy and ovarian drilling followed by clomiphene and metformin. by means of this treatment, the patient usually regains their cycle and ovulation as the drilling decreases the level of androgen (9). Our patient also conceived and regained her cycle after her delivery.

Clinicians in Sudan must consider PCOS as an important cause of primary amenorrhea and a common cause of primary infertility.

### Acknowledgements

Our thanks are due to, Elhikma Company and all our colleagues in MAGS centre for their help and support.

### Author's Contribution

The two authors conduct the laparoscopy & wrote down the case report together. The second author here declares that he has no competing conflict of interest. No financial support in a case report.

### References

1. Lobo RA. *Primary and secondary amenorrhea and precocious puberty: Etiology, diagnostic evaluation, management*. 5th ed. Katz VL, Lentz GM, Lobo RA, Gershenson DM editors. Philadelphia, Pa: Mosby Elsevier; 2007.
2. Dunaif A, Thomas A. Current concepts in the polycystic ovary syndrome. *Annu Rev Med*. 2001;**52**:401-19.
3. *The Centers for Disease Control and Prevention; Infertility FAQ's*. 2009. Available from: <http://www.cdc.gov/>.
4. "Polycystic ovary syndrome"..
5. Ehrmann DA, Barnes RB, Rosenfield RL. Polycystic ovary syndrome as a form of functional ovarian hyperandrogenism due to dysregulation of androgen secretion. *Endocr Rev*. 1995;**16**(3):322-53.
6. *Polycystic Ovarian Syndrome Treatment & Management*". *eMedicine*. 2011. Available from: <http://emedicine.medscape.com/article/256806-treatment#showall>..
7. Mayo Clinic Staff.. "Polycystic Ovary Syndrome – All". *MayoClinic.com*. *Mayo Clinic*..
8. Legro RS, Barnhart HX, Schlaff WD, Carr BR, Diamond MP, Carson SA, et al. Clomiphene, metformin, or both for infertility in the polycystic ovary syndrome. *N Engl J Med*. 2007;**356**(6):551-66.
9. Farquhar C, Brown J, Marjoribanks J. Laparoscopic drilling by diathermy or laser for ovulation induction in anovulatory polycystic ovary syndrome. *Cochrane Database Syst Rev*. 2012;**6**:CD001122.
10. Nadir RF. *Evanthia Diamanti-Kandarakis, Diagnosis and Management of Polycystic Ovary Syndrome*. : Springer. p. 243.
11. Wafaa M, Barghash N, Fayrouz S. *Clinical, ultrasonographic and endocrine predictors of ovarian response to clomiphene citrate in normogonadotropic anovulatory infertility*..
12. *Polycystic Ovary Syndrome: Frequently Asked Questions*.. Available from: [Womenshealth.gov](http://Womenshealth.gov).
13. *National Institute for Health, and Clinical Excellence. Clinical guideline. assessment and treatment for people with fertility problems*. London: Fertility; 2004.